

Transcatheter pulmonary valve perforation using chronic total occlusion wire in pulmonary atresia with intact ventricular septum

Shweta Bakhru, Shilpa Marathe, Manish Saxena, Sudeep Verma, Rajan Saileela, Tapan K Dash¹, Nageswara Rao Koneti

Departments of Pediatric Cardiology and ¹Pediatric Cardiac Surgery, Care Hospital, The Institute of Medical Sciences, Hyderabad, Telangana, India

ABSTRACT

- Background** : Perforation of pulmonary valve using radiofrequency ablation in pulmonary atresia with intact ventricular septum (PA IVS) is a treatment of choice. However, significant cost of the equipment limits its utility, especially in the developing economies.
- Objective** : To assess the feasibility, safety, and efficacy of perforation of pulmonary valve using chronic total occlusion (CTO) wires in patients with PA IVS as an alternative to radiofrequency ablation.
- Methods** : This is a single-center, nonrandomized, retrospective study conducted during June 2008 to September 2015. Twenty-four patients with PA IVS were selected for the procedure during the study period. The median age and weight of the study population were 8 days and 2.65 kg, respectively. Four patients were excluded after right ventricular angiogram as they showed right ventricular-dependent coronary circulation. The pulmonary valve perforation was attempted using various types of CTO wires based on the tip load with variable penetrating characteristics.
- Results** : The procedure was successful in 16 of twenty patients using CTO wires: Shinobi in nine, Miracle in four, CROSS-IT in two, and Conquest Pro in one. Two patients had perforation of right ventricular outflow tract (RVOT). Pericardiocentesis was required in one patient to relieve cardiac tamponade. Later, the same patient underwent successful hybrid pulmonary valvotomy. The other patient underwent ductus arteriosus (DA) stenting. Balloon atrial septostomy was needed in three cases with systemic venous congestion. Desaturation was persistent in five cases necessitating DA or RVOT stenting to augment pulmonary blood flow. There were two early and two late deaths. The mean follow-up was 22.66 ± 16 months. Three patients underwent one and half ventricle repair and one Blalock–Taussig shunt during follow-up.
- Conclusion** : Perforation of the pulmonary valve can be done successfully using CTO wires in selected cases of pulmonary atresia with intact ventricular septum.
- Keywords** : Chronic total occlusion wire, percutaneous balloon dilatation of pulmonary valve, pulmonary atresia with intact ventricular septum, pulmonary valve perforation

Access this article online

Quick Response Code:



Website:

www.annalspc.com

DOI:

10.4103/0974-2069.197065

This is an open access article distributed under the terms of the Creative Commons Attribution-NonCommercial-ShareAlike 3.0 License, which allows others to remix, tweak, and build upon the work non-commercially, as long as the author is credited and the new creations are licensed under the identical terms.

For reprints contact: reprints@medknow.com

How to cite this article: Bakhru S, Marathe S, Saxena M, Verma S, Saileela R, Dash TK, *et al.* Transcatheter pulmonary valve perforation using chronic total occlusion wire in pulmonary atresia with intact ventricular septum. *Ann Pediatr Card* 2017;10:5-10.

Address for correspondence: Dr. Nageswara Rao Koneti, Department of Paediatric Cardiology, Care Hospital, Road No: 1, Banjara Hills, Hyderabad - 500 034, Telangana, India. E-mail: drkoneti@yahoo.com

INTRODUCTION

Pulmonary atresia with intact ventricular septum (PA IVS) is a serious congenital heart disease with an incidence of 0.008%–3.1%.^[1] It has a wide spectrum of clinical presentation ranging from cyanosis to shock due to closure of ductus arteriosus (DA).^[1,2] The treatment follows initial stabilization with prostaglandin and establishment of antegrade flow. Occasionally, systemic to pulmonary shunt or DA stenting may be necessary in addition to opening of pulmonary valve. Transcatheter radiofrequency ablation is routinely done in some centers; however, cost and availability of equipment limit its usage. Perforation of pulmonary valve using the stiff end of coronary guidewire has been reported, but this procedure is associated with complications due to less control on the perforating system.^[3,4]

Wide varieties of chronic total occlusion (CTO) wires are used during coronary angioplasty to cross the totally occluded arteries. The stiffness, weight of the tip of the wire, and a specific character called as “penetrating power” determine their usage in crossing the occluded vessel. In our series, we report the use of different types of CTO wires to perforate pulmonary valve in patients with PA IVS.

METHODS

This is a single center experience from June 2008 to September 2015 consisting of 24 neonates and infants. All patients presented either with severe cyanosis or shock. Diagnosis of PA IVS was established by transthoracic echocardiography (TTE). Various parameters were analyzed namely, tricuspid annulus “z” score, severity of right ventricular hypoplasia, right ventricular outflow tract (RVOT) anatomy, size of arterial duct, interatrial communication, and branch pulmonary artery anatomy.

Inclusion criteria

- Neonates and infants with membranous PA IVS with patent infundibulum
- Tricuspid valve “z” score >–4.0.

Exclusion criteria

- Presence of right ventricular-dependent coronary circulation (RVDCC) by angiogram
- Absent infundibulum
- Tricuspid valve “z” score <–4.0
- Severe tricuspid regurgitation with cardiothoracic ratio >0.7.

Procedure [Figure 1a-d]

The procedure was performed under general anesthesia after obtaining high-risk informed consent from parents. Both femoral vein and femoral arterial accesses were

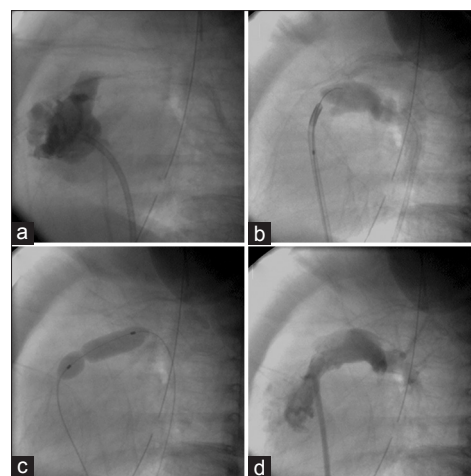


Figure 1: (a) Cine angiogram in lateral view showing heavily trabeculated right ventricle with membranous pulmonary atresia; (b) retrograde angiogram through ductus arteriosus confirming the site of perforation using chronic total occlusion wire; (c) final balloon dilation showing indentation at valvular level; (d) postballoon right ventricle angiogram demonstrating good antegrade flow into pulmonary artery

obtained under strict aseptic conditions by Seldinger’s technique. 5F and 4F sheaths were introduced into femoral vein and femoral artery, respectively. A 4F 1.5 or 2.0 curve Judkins right (JR) coronary catheter (Cooks medical, Bloomington, USA) was used to enter right ventricle (RV). Placing catheter inside RV is challenging due to the presence of tricuspid regurgitation, RV hypertrophy, or hypoplasia. Hence, right atrial angiogram in anterior-posterior projection was done in selected cases to delineate right ventricular inflow anatomy. RV angiogram was performed as a routine in all cases, and subsequently, aortogram was done to exclude RVDCC. The catheter was advanced with clockwise rotation to face the RVOT. Further negotiation of JR catheter was done to face pulmonary valve. Descending aortic angiogram in lateral view at the level of DA was done and found useful to confirm the main pulmonary artery, pulmonary valve dimple, and its sinuses to decide the site of perforation [Figure 1a and b]. The JR catheter was maintained at the site of perforation close to the pulmonary valve. CTO wire either Shinobi (Cordis Corporation, NJ, USA) or Miracle (Abbott Laboratories, Illinois, USA) or CROSS-IT (Abbott Laboratories, Illinois, USA), or Conquest Pro (Asahi Intecc Co. Ltd., Aichi, Japan) was used to perforate the pulmonary valve. Initially, low penetration wire was used for perforation. However, in some cases, high penetration wire had to be used due to unsuccessful perforation with low penetration wire. Furthermore, it was found out during the course of the study that hydrophilic wire such as Shinobi and those with higher tip load had higher success rate. Details of the wire properties are given in Table 1.

Table 1: Wire type, coating, tip load, and penetrating force

Wire	Manufacturer	Coating	Tip load	Penetration force kg/in ²
Miracle 3	Abbott	Hydrophobic	3.0	20
Miracle 6	Abbott	Hydrophobic	6.0	39
Miracle 12	Abbott	Hydrophobic	12.0	78
CROSS-IT 100	Abbott	Hydrophilic	1.7	22
CROSS-IT 200	Abbott	Hydrophilic	4.7	60
CROSS-IT 300	Abbott	Hydrophilic	6.2	79
CROSS-IT 400	Abbott	Hydrophilic	8.7	110
Shinobi	Cordis	Hydrophilic	2.0	13
Shinobi plus	Cordis	Hydrophilic	4	26
Conquest	Asahi	Hydrophobic	9.0	142
Conquest Pro	Asahi	Hydrophilic	9.0	142
Conquest Pro12	Asahi	Hydrophilic	12.0	189

The wire was preshaped so that the tip remained coaxial to JR catheter against the pulmonary valve. Then, the wire was gently manipulated and advanced in controlled fashion keeping the catheter close to the valve using a torquer. The distance between catheter and the distal tip of the wire required to be adjusted to perforate the valve with a gentle push. The position of guidewire was confirmed by DA angiogram to detect RVOT perforation [Figure 2a and b]. In most cases, atretic membranous pulmonary valve was perforated using this technique. The guidewire was further negotiated to enter into descending aorta through DA or distal branch pulmonary artery with careful manipulation. The wire was exteriorized from descending aorta, whenever possible, using a 10 mm goose neck snare (Ev3 Endovascular, Inc., Plymouth, MN, USA) to have a stable guidewire position.

A 1.5 mm × 15 mm coronary balloon (Ryujin Plus, Terumo Medical Corporation, Japan) was advanced over the wire to perform dilatation. The size of the balloon was upgraded from 1.5 to 8 mm diameter during serial dilations depending on the measured annulus size. The final balloon size was chosen to achieve 120%–150% of the pulmonary annulus size [Figure 1c and d]. Postdilatation pull back gradient was recorded through a Tuohy-Borst connector using JR catheter. RV angiogram was routinely done in all cases after the dilatation.

Stenting of DA or RVOT was done in cases with persistent desaturation (<70%) after pulmonary valve dilation. Transvenous approach was used to stent DA using 5F JR guide catheter. An appropriate size stent was deployed to maintain DA patency.

Balloon atrial septostomy (BAS) was done in cases with systemic venous congestion and restrictive foramen ovale. The decision of BAS was taken based on the evidence of refractory right heart failure. The adequacy of the interatrial communication was assessed by transthoracic echocardiogram.

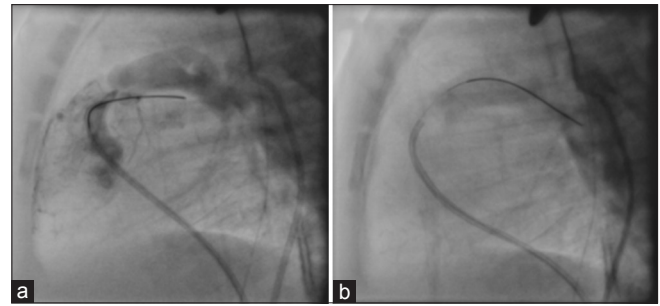


Figure 2: Cine angiogram showing (a) right ventricular outflow tract perforation confirmed by simultaneous right ventricle and ductus arteriosus angiogram; (b) proper pulmonary valve perforation confirmed by ductus arteriosus angiogram

RESULTS

The baseline parameters and procedure details of successful cases are summarized in Table 2. Twenty cases (female: 11) were eligible for pulmonary valve perforation. Median age of the study population was 18 days (3–332 days). The median weight was 2.65 kg (2.2–7.1 kg) and mean tricuspid valve “z” score was -2.09 ± 0.7 . Four cases were excluded after angiogram due to RVDCC. Two of these cases underwent DA stenting whereas other two underwent modified Blalock-Taussig (BT) shunt. The valve was successfully perforated in 16 out of twenty patients; ten cases using single CTO wire, and six cases with multiple CTO wires. The perforation was achieved with Shinobi in nine, Miracle in four, CROSS-IT in two, and Conquest Pro wire in one case. CTO wire was exteriorized in nine cases through the descending aorta.

Complications

Cardiac tamponade due to RVOT was seen in one patient. Baby became stable after pericardiocentesis and underwent hybrid pulmonary valve perforation and DA stenting at a later date.

Additional procedures

- Persistent low saturation (<70%) was noticed in four cases after the perforation. These patients improved after DA stenting. Case no. 10 presented on follow-up with worsening cyanosis due to infundibular obstruction. An emergency RVOT stenting was done to ameliorate saturation
- BAS was performed in three cases with systemic venous congestion and restrictive interatrial communication. These patients improved after the procedure.

Morbidity and mortality

Congestive heart failure due to circular shunt was seen in two cases of which one improved with conservative management.

Table 2: Baseline characteristics of the study population

Case number	Age (days)	Weight (kg)	Chronic total occlusion wire	Procedure	Pre- and post-RV pressures		Additional procedure	Outcome on follow-up	Preprocedure tricuspid “z” score
1	25	2.6	Shinobi	Successful PV perforation	210	50	PDA stenting, BAS	On follow-up	−2
2	15	3	Shinobi	Successful PV perforation	88	40	Nil	Died after 3 months	−1.2
3	20	2.8	Shinobi	Successful PV perforation	96	52	Nil	1.5 ventricle repair	−2
4	18	2.4	Miracle	Successful PV perforation	62	36	BAS	1.5 ventricle repair	−1.9
5	22	3	Miracle	Successful PV perforation	109	46	BAS	On follow-up	−1.6
6	20	2.2	CROS IT 100	Successful PV perforation	120	70	Nil	BT shunt	−1.6
7	153	5.5	Miracle	Successful PV Perforation	130	68	Nil	Died due to sepsis	−1.8
8	12	2.2	CROSS-IT 200	Attempted PV perforation, procedure abandoned due to tamponade	108	66	Hybrid pulmonary valvotomy PDA stenting	Died on follow-up	−1.8
9	15	2.4	Shinobi	Successful PV perforation	130	70	PDA stenting	On follow-up	−3.8
10	30	2.2	Shinobi	Successful PV perforation	126	68	RVOT stenting	On follow-up	−3.2
11	95	4.5	Shinobi	Successful PV perforation	150	60	Nil	On follow-up	−1.5
12	331	7.1	Shinobi	Successful PV perforation	87	55	Nil	Death on follow-up due to febrile illness	NA
13	19	4	Shinobi, Miracle	Successful PV perforation	60	48	Nil	On follow-up	NA
14	11	2.3	Shinobi	Successful PV perforation	104	60	Nil	On follow-up	−1.49
15	3	3.2	Shinobi	Successful PV perforation	110	36	PDA stenting	Death on postprocedure day 3 due to heart failure	NA
16	15	2.4	Shinobi	RVOT perforation, no tamponade	70		PDA stenting	Death on follow-up	−2.2
17	4	2.4	Shinobi	Failed PV perforation	80		PDA stenting	Death on follow-up	NA
18	5	2.3	Shinobi	Failed PV perforation	90		PDA stenting	On follow-up	−2.8
19	62	3.2	Shinobi	Successful PV perforation	60	40	Nil	On follow-up	−2.86
20	11	3.0	Conquest-pro	Successful PV perforation	110	36	PDA stenting	On follow-up	−1.8

PDA: Patent ductus arteriosus, BAS: Balloon atrial septostomy, BT: Blalock–Taussig, NA: Not applicable, RVDCC: Right ventricular dependent coronary circulation, RVOT: Right ventricular outflow tract, PV: Pulmonary valve, RV: Right ventricular

Early death is defined as “in-hospital death after the procedure.” There were two deaths in early postprocedure period secondary to sepsis (case no. 7) and circular shunt (case no. 15). There were two late deaths identified by telephonic interrogation during the follow-up period. Case no. 2 died due to unidentified cause 3 months after procedure, whereas case no. 12 died 1 year after procedure due to febrile illness [Flow Chart 1].

The mean follow-up period was 22.66 ± 16 months. The follow-up assessment included pulse oximetry, chest X-ray, electrocardiogram, and TTE. The mean systemic

saturation was $85 \pm 5.7\%$ during follow-up. TTE showed a significant improvement in right ventricular size [Figure 3] and mean tricuspid valve “z” score from -2.2 ± 0.7 to -1.31 ± 1.2 during follow-up. Three children underwent bidirectional Glenn surgery on follow-up due to low systemic saturation ($<80\%$). One child underwent BT shunt due to hypoplastic pulmonary arteries and desaturation.

DISCUSSION

Pulmonary atresia with intact septum is a spectrum of congenital heart disease with varying degree of right

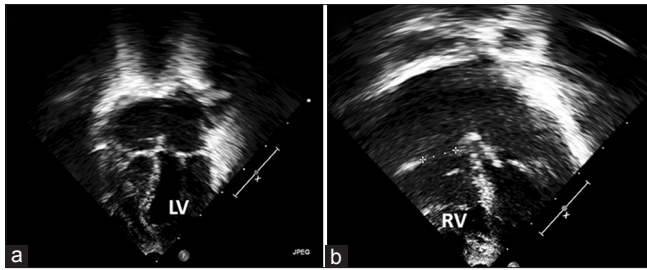
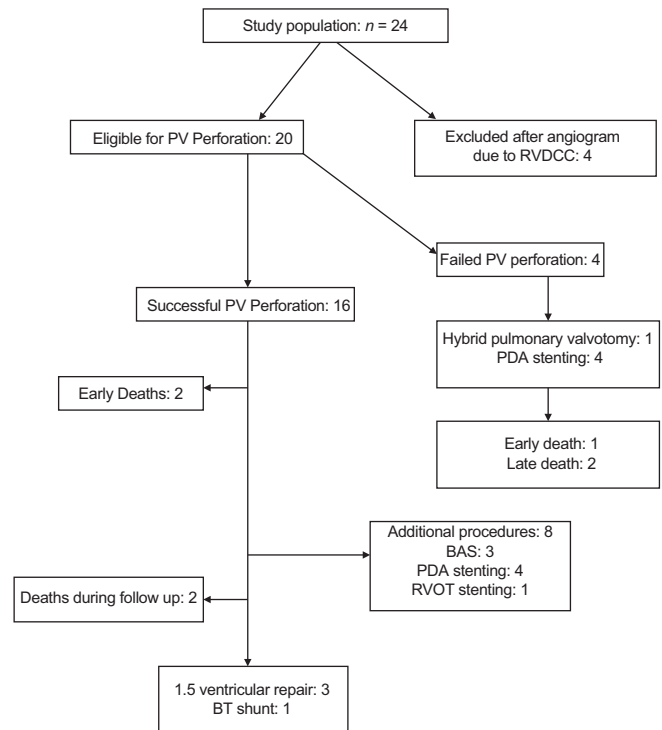


Figure 3: Transthoracic echocardiography apical four-chamber view in a case showing (a) hypoplastic diminutive right ventricle before procedure; (b) well-developed right ventricle during follow-up after pulmonary valve perforation. RV: Right ventricle; LV: Left ventricle

ventricular and tricuspid valve hypoplasia presenting in neonatal life.^[1,2,5] Initial stabilization with prostaglandin and establishment of pulmonary flow is the first stage of palliation.^[5] Latson *et al.* in 1991 performed the first case of valvular opening with the rigid tip of a guidewire; however, it is technically challenging and associated with complications.^[3,4] Subsequently, Qureshi *et al.* and Parsons *et al.* used laser to perforate the pulmonary valve.^[6,7] Currently, perforation of pulmonary valve using radiofrequency wire is the most accepted and established method of dealing with this anomaly. However, cost constraints limit the availability of this equipment in resource-limited countries.^[8]

The use of CTO wire for pulmonary valve perforation is thought as a good alternative in view of its peculiar property called as “penetration power.” Wide range of wires are available according to various penetrating powers and are commonly used in coronary interventions. The penetrating power of the guidewire depends on the tip stiffness and area of the wire. Two types of CTO wires are currently available - polymer coated hydrophilic and hydrophobic coil wires.^[9,10] Hydrophilic coating attracts very little resistance when they come in contact with tissue in the lumen. It moves easily through soft tissue and therefore has a potential risk of perforation. These wires, however, offer good maneuverability. We successfully perforated the pulmonary valve by hydrophilic wires in most of the cases. The coil wires provide less maneuverability but provide good resistance and torquability. The major advantage of these wires, as compared to the hard end of the coronary guidewires, is catheter stability during perforation which allows precise and controlled perforation.

In our small series, successful perforation was achieved in 16 of twenty cases of membranous valvular pulmonary atresia. To avoid RV wall perforation as seen in two of the cases, it is advisable to keep the “wire catheter assembly” on pulmonary valve dimple. This can be identified by simultaneous RVOT and DA angiogram. Subsequent serial dilations with incremental balloon diameter established good antegrade flow in most of



Flow Chart 1: The distribution of the study population and their course (RV: Right ventricle; PDA: Patent ductus arteriosus; BAS: Balloon atrial septostomy; RVOT: Right ventricular outflow tract; ASD: Atrial septal defect)

the cases. We used higher penetrating power CTO wires in some of the cases, in which low penetrating power wires were unsuccessful in perforating the valve. In six patients, multiple wires were attempted sequentially to achieve perforation. This suggests that the predictability of CTO wire with low penetration power is uncertain. Alwi *et al.* in their recently published series used Conquest Pro CTO wire.^[11] They could perforate the pulmonary valve in seven of eight cases without any complications. Only one patient needed radiofrequency ablation due to improper engagement of the CTO wire. This suggests CTO wire is a good alternative in properly selected cases with favorable right ventricular anatomy.

Initial results showed better outcome with radiofrequency ablation than surgical opening of RVOT and BT shunt.^[12-14] Thus, transcatheter therapy is the procedure of choice in those with suitable anatomy.^[15] Outcomes of radiofrequency and CTO wire perforation are comparable. Alwi *et al.*^[16] used radiofrequency ablation for pulmonary perforation with an immediate success of 84%. Twelve of the 16 successfully perforated cases achieved biventricular repair in their series. In our study, immediate success was seen in 80%, eight cases required additional procedures (four DA stenting, one RVOT stenting, and three BAS) in the immediate postprocedure period. Three patients required 1.5 ventricular repair and the remaining patients are on follow-up.

CONCLUSION

Utility of CTO wires in congenital heart intervention is limited. Our experience shows that CTO wires can be used to perforate the atretic pulmonary valve in selected population of PA IVS. It is probably an effective alternative to radiofrequency wire in resource-limited setting. More data from different centers will be helpful to confirm the safety and efficacy of this technique.

Limitations

This is a retrospective, observational study from a single center consisting of a small number of selected patients with PA IVS. Hence, results cannot be generalized to all the cases with membranous pulmonary atresia. CTO wires have variable penetrating power; therefore, operator experience is important in determining the type of wire/wires to be used in a given case.

Financial support and sponsorship

Nil.

Conflicts of interest

There are no conflicts of interest.

REFERENCES

1. Nykanen DG. Pulmonary atresia and intact ventricular septum. In: Allen HD, Driscoll DJ, Shaddy RE, Feltes TF, editors. Moss and Adams' Heart Disease in Infants, Children, and Adolescents. 7th ed. Baltimore, MD: Williams and Wilkins; 2008. p. 859-72.
2. Freedom RM. Pulmonary atresia and intact ventricular septum. In: Freedom RM, Mawson JB, Yoo SJ, Benson LM, editors. Congenital Heart Disease. Textbook of Angiocardiography. 2nd ed., Vol. 1. Wiley-Blackwell; 1997. p. 617-62.
3. Latson LA. Non surgical treatment of a neonate with pulmonary atresia and intact ventricular septum by transcatheter puncture and balloon dilation of the atretic valve membrane. Am J Cardiol 1991;68:277-9.
4. Pinto RI, Dalvi B. Transcatheter guidewire perforation of the pulmonary valve as a palliative procedure in pulmonary atresia with intact interventricular septum. Indian Heart J 2004;56:661-3.
5. Alwi M. Management algorithm in pulmonary atresia with intact ventricular septum. Catheter Cardiovasc Interv 2006;67:679-86.
6. Qureshi SA, Rosenthal E, Tynan M, Anjos R, Baker EJ. Transcatheter laser-assisted balloon pulmonary valve dilation in pulmonic valve atresia. Am J Cardiol 1991;67:428-31.
7. Parsons JM, Rees MR, Gibbs JL. Percutaneous laser valvotomy with balloon dilatation of the pulmonary valve as primary treatment for pulmonary atresia. Br Heart J 1991;66:36-8.
8. Rosenthal E, Qureshi SA, Chan KC, Martin RP, Skehan DJ, *et al.* Radiofrequency-assisted balloon dilatation in patients with pulmonary valve atresia and an intact ventricular septum. Br Heart J 1993;69:347-51.
9. Yamane M. Current percutaneous recanalization of coronary chronic total occlusion. Rev Esp Cardiol (Engl Ed) 2012;65:265-77.
10. Touma G, Ramsay D, Weaver J. Chronic total occlusions - Current techniques and future directions. IJC Heart Vasc 2015;7:28-39.
11. Alwi M, Budi RR, Mood MC, Leong MC, Samion H. Pulmonary atresia with intact septum: The use of Conquest Pro coronary guidewire for perforation of atretic valve and subsequent interventions. Cardiol Young 2013;23:197-202.
12. Giusti S, Spadoni I, De Simone L, Carminati M. Radiofrequency perforation in pulmonary valve atresia and intact ventricular septum. G Ital Cardiol 1996;26:391-7.
13. Cheatham JP, Coe JY, Kugler JD, Fletcher SE, Tower AJ. Successful transcatheter perforation of the atretic pulmonary valve membrane in a newborn using the new Coe radiofrequency end hole catheter. Cathet Cardiovasc Diagn 1998;45:162-6.
14. Justo RN, Nykanen DG, Williams WG, Freedom RM, Benson LN. Transcatheter perforation of the right ventricular outflow tract as initial therapy for pulmonary valve atresia and intact ventricular septum in the newborn. Cathet Cardiovasc Diagn 1997;40:408-13.
15. Agnoletti G, Piechaud JF, Bonhoeffer P, Aggoun Y, Abdel-Massih T, Boudjemline Y, *et al.* Perforation of the atretic pulmonary valve. Long-term follow-up. J Am Coll Cardiol 2003;41:1399-403.
16. Alwi M, Geetha K, Bilkis A. Pulmonary valve atresia with intact ventricular septum: Percutaneous radiofrequency-assisted valvotomy and balloon dilation versus surgical valvotomy and Blalock Taussig shunt. J Am Coll Cardiol 2000;35:468-76.