

ORIGINAL ARTICLE

Comparison of the efficacy and safety of indomethacin, ibuprofen, and paracetamol in the closure of patent ductus arteriosus in preterm neonates – A randomized controlled trial

Vasudha Meena¹, Durga Shankar Meena², Pradeep Singh Rathore¹, Sandeep Chaudhary¹, Jai Prakash Soni¹

¹Department of Paediatric Medicine, Division of Paediatric Cardiology, Dr. S. N. Medical College, MDM Hospital for Mother and Child, Jodhpur, Rajasthan, India, ²Department of Medicine, AIIMS, Jodhpur, Rajasthan, India

ABSTRACT

- Introduction** : In this prospective study, we compared the efficacy and safety of ibuprofen, indomethacin, and paracetamol in the closure of patent ductus arteriosus (PDA) in preterm neonates.
- Materials and Methods** : This randomized prospective study was conducted in the Division of Pediatric Cardiology, M. D. M and Umaid Hospital, Jodhpur. A total of 105 preterm neonates with gestational age <37 weeks and hemodynamically significant PDA (hs-PDA) diagnosed clinically and confirmed by echocardiography were enrolled. All neonates were randomly assigned in a ratio of 1:1:1 to oral indomethacin (Group A, 3 doses at an interval of 12 h with a starting dose of 0.2 mg/kg), oral ibuprofen (Group B, 10 mg/kg ibuprofen followed by 5 mg/kg/day for 2 days), or IV paracetamol (Group C, 15 mg/kg every 6 hourly for 3 consecutive days). After the completion of the first course, neonates were assessed clinically as well as by echocardiography to confirm PDA closure. If PDA remained open, the second course of the same drug was given and repeat assessment was done within 24 h of the last dose. In addition to an echocardiographic examination, complete blood counts, renal and liver function tests were performed.
- Results** : Our study shows that there was no significant difference observed in PDA closure among all the three treatment groups after the completion of two courses of treatment. The cumulative rate of PDA closure was 68% in the indomethacin group, 77.14% in the ibuprofen group, and 71.43% in the paracetamol group ($P = 0.716$). There were no significant changes found in Hb, platelet, blood urea nitrogen (BUN), creatinine, and liver enzymes after treatment in the paracetamol group ($P > 0.05$). BUN and serum creatinine levels were significantly increased after treatment in indomethacin and ibuprofen groups ($P < 0.0001$ and $P < 0.05$, respectively).
- Conclusion** : Our study shows that IV paracetamol is as effective as indomethacin and ibuprofen in promoting the closure of hs-PDA in premature infants with a better safety profile.
- Keywords** : Doppler, echocardiography, patent ductus arteriosus, rescue drugs

This is an open access journal, and articles are distributed under the terms of the Creative Commons Attribution-NonCommercial-ShareAlike 4.0 License, which allows others to remix, tweak, and build upon the work non-commercially, as long as appropriate credit is given and the new creations are licensed under the identical terms.

For reprints contact: reprints@medknow.com

How to cite this article: Meena V, Meena DS, Rathore PS, Chaudhary S, Soni JP. Comparison of the efficacy and safety of indomethacin, ibuprofen, and paracetamol in the closure of patent ductus arteriosus in preterm neonates – A randomized controlled trial. *Ann Pediatr Card* 2020;13:130-5.

Access this article online

Quick Response Code:



Website:

www.annalspc.com

DOI:

10.4103/apc.APC_115_19

Address for correspondence: Dr. Jai Prakash Soni, Shivam Hospital, Bhaskar Circle, Ratanada, Jodhpur - 342 011, Rajasthan, India.

E-mail: doc_jpsoni@yahoo.com

Submitted: 13-Aug-2019

Revised: 15-Oct-2019

Accepted: 09-Dec-2019

Published: 14-Feb-2020

INTRODUCTION

Patent ductus arteriosus (PDA) is defined as the failure of the ductus arteriosus (DA) to close within 72 h after birth.^[1] The reported incidence of PDA in preterm neonates ranges from 20% to 60%.^[2] A persistent PDA can cause significant problems, especially in premature infants. Thus, the early closure of PDA is important to prevent complications in preterm babies such as necrotizing enterocolitis, intraventricular hemorrhage (IVH), and bronchopulmonary dysplasia, etc.^[3-5] There has been a lack of consensus regarding the treatment of PDA which includes conservative approach (fluid restriction and watchful waiting), pharmacological closure using cyclo-oxygenase (COX) inhibitors indomethacin, ibuprofen or acetaminophen, and surgical ligation.

There have not been large randomized controlled trials comparing pharmacologic management of PDA versus conservative approach and surgical ligation. There are several limitations of nonsteroidal anti-inflammatory drugs (NSAIDs) with concern regarding their safety profile. Renal dysfunction, gastrointestinal (GI) hemorrhage, increased bilirubin, and thrombocytopenia are few important adverse effects in neonates treated with NSAIDs.^[6-8] There are published trials comparing indomethacin with ibuprofen and paracetamol with other NSAIDs. Only one randomized control trial has compared the efficacy and safety of paracetamol, ibuprofen, and indomethacin in the closure of PDA in preterm neonates.^[9] Considering the promising effect of paracetamol in PDA closure as a safer alternative, we undertook this study to compare the safety profile and efficacy of all the three-mentioned drugs. To the best of our knowledge, we believe that this is the first study from India to do so.

MATERIALS AND METHODS

We planned a randomized prospective study. It was conducted in the Division of Pediatric Cardiology, Department of Pediatrics, M. D. M and Umaid Hospital, Dr S. N. Medical College, Jodhpur. The study duration was 1 year and the study was conducted after the Institutional Ethical Committee approval. The nature, purpose, and possible risks of the drug were explained to the parents in detail before obtaining written consent. Preterm neonates with gestational age <37 weeks, in the first 28 postnatal days of life with hemodynamically significant PDA (hs-PDA), diagnosed clinically and confirmed by echocardiography were included in the study. Neonates with major congenital anomalies, all right- and left-sided PDA-dependent congenital heart diseases, life-threatening infections; recent (within previous 24 h) IVH (Grade 3 and 4), urine output

less than 0.6 ml/kg/h, blood urea >40 mg/dl, serum creatinine >1.8 mg/dl, platelet count <60,000/mm³, hyperbilirubinemia requiring exchange transfusion, active necrotizing enterocolitis (NEC) and/or intestinal perforation, active bleeding, and evidence of birth asphyxia (APGAR score below 5 at 5 min and/or umbilical cord pH <7.0 at birth) were excluded from the study.

Primary outcome

To determine the rate of PDA closure after the first and second course of drugs and to determine the number of neonates requiring rescue drug therapy for PDA closure in all groups. The secondary outcome was to compare the side effects and complications in each group.

Clinical criteria for the diagnosis of hs-PDA were tachycardia, bounding pulse with wide pulse pressure, hyperdynamic precordium with continuous murmur on auscultation, hepatomegaly, and the failure of respiratory distress syndrome to improve within 2–7 days.^[10] The following were the echocardiography criteria for hs-PDA: internal diameter of the duct >1.5 mm, left atrial dilatation (LA/Ao >1.4), diastolic turbulence (backflow) on Doppler in the pulmonary artery, and reversed end-diastolic flow in the descending aorta/mesenteric artery.^[11]

The parents of neonates who met the inclusion criteria were briefed about the study and informed written consent was obtained to participate in the study. All eligible neonates were randomly assigned in a ratio of 1:1:1 among oral indomethacin, oral ibuprofen, and intravenous (IV) paracetamol groups.

In Group A (indomethacin group), oral indomethacin (3 doses at 12 hourly intervals) with starting dose of 0.2 mg/kg followed by 0.1 mg/kg for babies <2 days of age, 0.2 mg/kg for 2–7 days of postnatal life, and 0.25 mg/kg for >7 days of postnatal life was given.

In Group B (ibuprofen group), oral ibuprofen at the initial dose of 10 mg/kg followed by 5 mg/kg after 24 and 48 h was given.

In Group C (paracetamol group), IV paracetamol at 15 mg/kg every 6 hourly for 3 consecutive days was given.

In each group, all enrolled neonates were given respective drugs, and after the completion of the first course, neonates were assessed clinically as well as by echocardiography to confirm PDA closure within 24 h of the last dose. If PDA remained open, the second course of the same drug was repeated and repeat clinical as well as echo assessment was done within 24 h of the last dose. If PDA failed to close after the second dose, then neonates were given sequential rescue drugs after repeating blood investigations. Neonates were followed up a week after PDA closure by echocardiography to reassess PDA patency.

The echocardiographic scan was done by a pediatric cardiologist using Philips EPIQ 7C ultrasound scanner located in our department. Each neonate enrolled in the study underwent scans in a thermoneutral environment under aseptic precautions. The scan was performed as per the guideline and recommendation for the targeted neonatal echocardiography in the neonatal intensive care unit.^[12] The various PDA-related parameters were assessed and noted on the predesigned pro forma for this study.

Cranial ultrasound scanning was done before and after treatment to detect an IVH.

The data obtained were analyzed using Microsoft Excel 2010 with the help of SPSS (version 20.0, IBM Corp., Armonk, N.Y., USA) software. The results were expressed as mean values \pm standard deviation. Categorical data of the sample were presented as number (%). The statistical analysis was performed using a Student's *t*-test and Chi-square test to find the significance of the difference in mean between two variables. In our study, $P < 0.05$ was considered as significant with either negative or positive correlation on account of the biological variability.

RESULTS

A total of 105 preterm neonates were randomized into three groups (indomethacin, ibuprofen, and paracetamol). In each group, 35 patients were assessed for the closure of PDA. The baseline demographic and echocardiographic data of preterm infants were not statistically different [Table 1]. All baseline investigations in different treatment groups were also not statistically different [Table 2]. Our study shows there was no significant difference observed in PDA closure among the treatment groups after the completion of two courses of the treatment. The rate of closure after the first course was 22.86% in the indomethacin group, 37.14% in the ibuprofen group, and 42.46% in the paracetamol group [Table 3 and Figure 1]. The cumulative rate of PDA closure was 68% in the indomethacin group, 77.14% in the ibuprofen group, and 71.43% in the paracetamol group ($P = 0.716$).

In Group A, no significant difference was observed in hemoglobin and platelet counts after indomethacin treatment ($P = 0.638$), while blood urea nitrogen and

serum creatinine levels significantly increased after the treatment ($P < 0.0001$). There was no change noted in pre- and posttreatment values of liver enzymes ($P > 0.05$).

In Group B, who were treated with oral ibuprofen as a primary drug, there were no significant changes noted in hemoglobin, platelet, and liver enzymes ($P > 0.05$). Serum creatinine and blood urea nitrogen (BUN) were found to be significantly increased after the ibuprofen treatment ($P < 0.05$) [Table 2].

In Group C, who were given paracetamol as the primary drug, there was no significant change in Hb, platelet, BUN, creatinine, and liver enzyme after the treatment ($P \geq 0.05$).

NEC and GI tract bleeding were observed in 5.71% and 2.86% of the neonates, respectively, after indomethacin therapy, while it was 2.86% and 2.86%, respectively [Table 4], in the ibuprofen group. No GI bleeding and NEC occurred in patients after paracetamol therapy. Pulmonary hemorrhage was seen in 2.86% of the neonates in both indomethacin and paracetamol groups. No pulmonary hemorrhage occurred in any patient treated with ibuprofen. This was not statistically significant.

DISCUSSION

hs-PDA in preterm neonates is often associated with complications. Among various treatment modalities,

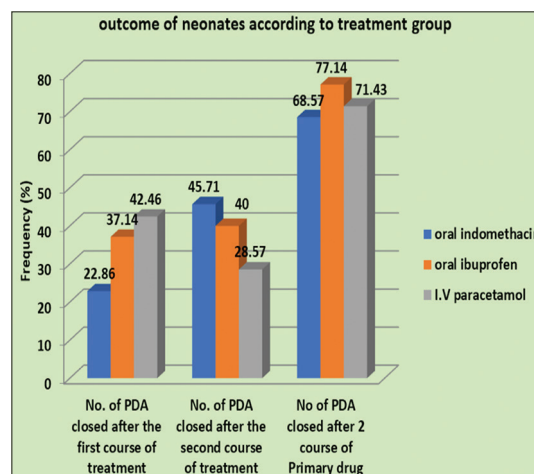


Figure 1: Patent ductus arteriosus closure in neonates according to the treatment group

Table 1: Baseline characteristics and echocardiographic data of preterm infants in all the studied groups

	Group A (indomethacin) (n=35)	Group B (ibuprofen) (n=35)	Group C (paracetamol) (n=35)	ANOVA (P)
Gestational age (weeks)	31.77 \pm 2.26	31.42 \pm 1.72	32.14 \pm 2.01	0.335
Sex (male: female)	15:20	14:21	18:17	0.342
Weight (kg)	1.41 \pm 0.32	1.34 \pm 0.22	1.44 \pm 0.34	0.323
Age at start of medication (days)	10.85 \pm 4.25	10.77 \pm 5.63	9.02 \pm 3.43	0.167
PDA size (mm)	1.82 \pm 0.28	1.95 \pm 0.75	1.85 \pm 0.43	0.551
Left atrial/aortic root ratio	1.74 \pm 0.20	1.72 \pm 0.20	1.72 \pm 0.22	0.889

PDA: Patent ductus arteriosus

Table 2: Investigation before and after patent ductus arteriosus closure

Investigations	Group A		P	Group B		P	Group C		P
	Before (n=35)	After (n=35)		Before (n=35)	After (n=35)		Before (n=35)	After (n=35)	
Hb	16.57±2.80	16.63±2.97	0.638	17.10±2.32	17.05±2.30	0.522	16.54±2.17	16.38±12.11	0.692
Platelet	184.11±79	181.67±77	0.833	198.28±79	190.06±64	0.117	183.05±71	172.028±66	0.435
Blood urea	30.05±7.02	43.42±7.30	<0.0001	27.97±6.68	34.74±8.59	<0.0001	29.85±8.37	30.34±10.23	0.766
Serum creatinine	0.87±0.26	1.01±0.26	<0.0001	0.85±0.35	0.92±0.34	0.005	0.79±0.17	0.76±0.23	0.560
SGOT	30.48±11.33	31.51±9.91	0.422	29.54±11.39	31.51±10.94	0.272	35.14±10.63	36.28±10.75	0.419
SGPT	26.74±9.05	29.34±8.15	0.127	26.17±9.27	27.17±7.85	0.528	29.28±11.35	30.74±9.38	0.409

PDA: Patent ductus arteriosus, Hb: Hemoglobin, SGOT: Serum glutamic oxaloacetic transaminase, SGPT: Serum glutamic pyruvic transaminase

Table 3: Outcome of neonates according to the treatment group

Parameters	Group A (oral indomethacin) (n=35), n (%)	Group B (oral ibuprofen) (n=35), n (%)	Group C (IV paracetamol) (n=35), n (%)	P value Chi-square test for independence
Primary outcome				
Number of PDA closed after the first course of treatment	8 (22.86)	13 (37.14)	15 (42.85)	0.912
Number of PDA closed after the second course of treatment	16 (45.71)	14 (40.00)	10 (28.57)	0.660
Total number of PDA closed after two courses of primary drug	24 (68.57)	27 (77.14)	25 (71.42)	0.716

IV: Intravenous

Table 4: Spectrum of adverse effects observed in three different groups

Side effects	Group A, n (%)	Group B, n (%)	Group C, n (%)	Total, n (%)	P (ANOVA)
NEC	2 (5.71)	1 (2.86)	0	3 (2.86)	0.357
GIT bleed	1 (2.86)	1 (2.86)	0	2 (1.90)	0.600
Pulmonary bleed	1 (2.86)	0	1 (2.86)	2 (1.90)	0.357

NEC: Necrotizing enterocolitis, GIT: Gastrointestinal tract

pharmacotherapy seems to be the therapy of choice before any device or surgical intervention because its proven safety and effectiveness in the treatment of the hs-PDA in preterm neonates.^[13,14] COX inhibitors such as indomethacin and ibuprofen were historically used for the closure of PDA. However, new studies have shown that paracetamol could be an alternative therapeutic approach for the ductal closure. Paracetamol has been evaluated in many trials, which is as effective as traditional NSAIDs in PDA closure with fewer side effects.

Paracetamol is not a classical NSAID, and it reduces the synthesis of prostaglandins through the inhibition of prostaglandin H synthase (PGHS) similar to NSAIDs but acts on a different enzyme site called the peroxidase region.

To the best of our knowledge, there is only one previous study that has compared the efficacy and side effects of all three prostaglandin inhibiting drugs in preterm neonates done by El-Mashad *et al.*^[9] In their report all the three drugs were given intravenously, whereas in our study, the indomethacin and ibuprofen were given by oral route, while paracetamol was given intravenously. This is the first study of its kind from India, which has compared the efficacy and safety profile of indomethacin, ibuprofen, and paracetamol in preterm neonates.

Our study showed that paracetamol is as effective as indomethacin and ibuprofen for pharmacological ductal closure among preterm neonates. The rate of

ductal closure was 68.57%, 71.42%, and 77.17% with indomethacin, paracetamol, and ibuprofen therapy, respectively. Similar observations reported by El-Mashad *et al.* revealed that paracetamol is as effective as indomethacin and ibuprofen for ductal closure among preterm neonates.^[9] The rate of closure in their study was 80%, 81%, and 77% with paracetamol, indomethacin, and ibuprofen, respectively. Dash *et al.* found that the PDA closure rate was 95% in indomethacin group and 100% in paracetamol group,^[15] Yang *et al.* found that the ductal closure rate was 70.5% in the acetaminophen group and 77.6% in the ibuprofen group ($P = 0.506$).^[16] Oncel *et al.* reported 100% PDA closure with IV paracetamol administration.^[17] However, another study done by Roofthoof *et al.* showed disappointing results with IV paracetamol administration, as PDA closure was reported in only 18% of the patients with relatively low gestational age.^[18]

Comparing the side-effect profile of all three drugs, there were no significant changes seen in BUN and serum creatinine in the paracetamol group. The risk of renal dysfunction was more in the indomethacin group than in the ibuprofen group. Similar results were reported by El-Mashad *et al.*^[9] Earlier reports have shown that ibuprofen caused less vasoconstriction than indomethacin which results in less compromise of renal blood flow.^[14,19,20] Hammerman *et al.* reported that paracetamol could offer important therapeutic advantages over NSAIDs (e.g., indomethacin and ibuprofen), as paracetamol has no peripheral vasoconstrictive effect and can be given to infants with clinical contraindications to NSAIDs.^[21]

Meena, *et al.*: Comparison of Pharmacological therapy in PDA closure

There were no significant changes noted in serum glutamic oxaloacetic transaminase or serum glutamic pyruvic transaminase levels in all the three study groups. Jacqz Aigrain described that the metabolism of paracetamol changes with age and hepatotoxic effects are less in neonates than in older children.^[22] However, in contrast to our results, some studies have reported hepatotoxicity with paracetamol.^[23,24]

Our results showed that there was no significant change in the platelet level after treatment in all the three groups. Al-lawana *et al.* and some other studies reported the same results, with no significant change in the platelet level after treatment with paracetamol and ibuprofen.^[25,26] El-Mashad *et al.* showed a significant difference in the platelet level after treatment in both ibuprofen and indomethacin groups, while no thrombocytopenia occurred after paracetamol treatment.^[9]

NEC and GI bleeding were significantly increased in the indomethacin and ibuprofen groups with no GI bleeding, or NEC occurred in the patients treated with paracetamol therapy. The results of our study were in agreement with other reports.^[27,28] Topical injury and COX-1 inhibition-mediated prostaglandin suppression are the two possible mechanisms described for GI bleed.^[6] However, Dash *et al.* reported a high incidence of intestinal bleed with paracetamol.^[15]

Limitation of the study

Our study was limited by a relatively small number of patients and a lack of blinding of the caregivers to the study intervention. We did not follow all patients to assess long-term outcomes. Further long-term analysis will be required, especially for neurodevelopmental adverse effects. These limitations could be addressed in future studies.

CONCLUSION

The result of our study shows that IV paracetamol is as effective as indomethacin and ibuprofen in promoting closure of the hs-PDA in premature infants with better safety profiles.

Acknowledgment

The authors would like to acknowledge the contribution of Dr. Vikas Payal.

Financial support and sponsorship

Nil.

Conflicts of interest

There are no conflicts of interest.

REFERENCES

1. Clyman RI. Ibuprofen and patent ductus arteriosus. *N Engl J Med* 2000;343:728-30.
2. El Hajjar M, Vaksman G, Rakza T, Kongolo G, Storme L. Severity of the ductal shunt: A comparison of different markers. *Arch Dis Child Fetal Neonatal Ed* 2005;90:F419-22.
3. Jim WT, Chiu NC, Chen MR, Hung HY, Kao HA, Hsu CH, *et al.* Cerebral hemodynamic change and intraventricular hemorrhage in very low birth weight infants with patent ductus arteriosus. *Ultrasound Med Biol* 2005;31:197-202.
4. Lee LC, Tillett A, Tulloh R, Yates R, Kelsall W. Outcome following patent ductus arteriosus ligation in premature infants: A retrospective cohort analysis. *BMC Pediatr* 2006;6:15.
5. Schmidt B, Roberts RS, Fanaroff A, Davis P, Kirpalani HM, Nwaesei C, *et al.* Indomethacin prophylaxis, patent ductus arteriosus, and the risk of bronchopulmonary dysplasia: Further analyses from the Trial of Indomethacin Prophylaxis in Preterms (TIPP). *J Pediatr* 2006;148:730-4.
6. Peng S, Duggan A. Gastrointestinal adverse effects of non-steroidal anti-inflammatory drugs. *Expert Opin Drug Saf* 2005;4:157-69.
7. Pezzati M, Vangi V, Biagiotti R, Bertini G, Cianciulli D, Rubaltelli FF. Effects of indomethacin and ibuprofen on mesenteric and renal blood flow in preterm infants with patent ductus arteriosus. *J Pediatr* 1999;135:733-8.
8. Rheinlaender C, Helfenstein D, Walch E, Berns M, Obladen M, Koehne P. Total serum bilirubin levels during cyclooxygenase inhibitor treatment for patent ductus arteriosus in preterm infants. *Acta Paediatr* 2009;98:36-42.
9. El-Mashad AE, El-Mahdy H, El Amrousy D, Elgendy M. Comparative study of the efficacy and safety of paracetamol, ibuprofen, and indomethacin in closure of patent ductus arteriosus in preterm neonates. *Eur J Pediatr* 2017;176:233-40.
10. Alagarsamy S, Chhabra M, Gudavalli M, Nadroo AM, Sutija VG, Yugrakh D. Comparison of clinical criteria with echocardiographic findings in diagnosing PDA in preterm infants. *J Perinat Med* 2005;33:161-4.
11. McNamara PJ, Sehgal A. Towards rational management of the patent ductus arteriosus: The need for disease staging. *Arch Dis Child Fetal Neonatal Ed* 2007;92:F424-7.
12. Mertens L, Seri I, Marek J, Arlettaz R, Barker P, McNamara P, *et al.* Targeted neonatal echocardiography in the neonatal intensive care unit: Practice Guidelines and recommendations for training. *Eur J Echocardiogr* 2011;12:715-36.
13. Jones LJ, Craven PD, Attia J, Thakkestian A, Wright I. Network meta-analysis of indomethacin versus ibuprofen versus placebo for PDA in preterm infants. *Arch Dis Child Fetal Neonatal Ed* 2011;96:F45-52.
14. Starling MB, Elliott RB. The effects of prostaglandins, prostaglandin inhibitors, and oxygen on the closure of

- the ductus arteriosus, pulmonary arteries and umbilical vessels *in vitro*. Prostaglandins 1974;8:187-203.
15. Dash SK, Kabra NS, Avasthi BS, Sharma SR, Padhi P, Ahmed J. Enteral paracetamol or intravenous indomethacin for closure of patent ductus arteriosus in preterm neonates: A randomized controlled trial. Indian Pediatr 2015;52:573-8.
16. Yang B, Gao X, Ren Y, Wang Y, Zhang Q. Oral paracetamol vs. oral ibuprofen in the treatment of symptomatic patent ductus arteriosus in premature infants: A randomized controlled trial. Exp Ther Med 2016;12:2531-6.
17. Oncel MY, Yurttutan S, Degirmencioglu H, Uras N, Altug N, Erdevi O, *et al.* Intravenous paracetamol treatment in the management of patent ductus arteriosus in extremely low birth weight infants. Neonatology 2013;103:166-9.
18. Roofthoof DW, van Beynum IM, de Klerk JC, van Dijk M, van den Anker JN, Reiss IK, *et al.* Limited effects of intravenous paracetamol on patent ductus arteriosus in very low birth weight infants with contraindications for ibuprofen or after ibuprofen failure. Eur J Pediatr 2015;174:1433-40.
19. Dani C. Ibuprofen and paracetamol for patent ductus arteriosus. J Pediatr Neonat Individual Med 2014;3:e030226.
20. Van Overmeire B, Smets K, Lecoutere D, Van de Broek H, Weyler J, Degroote K, *et al.* A comparison of ibuprofen and indomethacin for closure of patent ductus arteriosus. N Engl J Med 2000;343:674-81.
21. Hammerman C, Bin-Nun A, Markovitch E, Schimmel MS, Kaplan M, Fink D. Ductal closure with paracetamol: A surprising new approach to patent ductus arteriosus treatment. Pediatrics 2011;128:e1618-21.
22. Jacqz-Aigrain E, Anderson BJ. Pain control: Non-steroidal anti-inflammatory agents. Semin Fetal Neonatal Med 2006;11:251-9.
23. Anderson BJ, Allegaert K. Intravenous neonatal paracetamol dosing: The magic of 10 days. Paediatr Anaesth 2009;19:289-95.
24. Alan S, Kahvecioglu D, Erdevi O, Atasay B, Arsan S. Is paracetamol a useful treatment for ibuprofen-resistant patent ductus arteriosus? Concerning the article by M.Y. Oncel *et al.*: Intravenous paracetamol treatment in the management of patent ductus arteriosus in extremely low birth weight infants [Neonatology 2013;103:166-169]. Neonatology 2013;104:168-9.
25. Al-Lawama M, Alammori I, Abdelghani T, Badran E. Oral paracetamol versus oral ibuprofen for treatment of patent ductus arteriosus. J Int Med Res 2018;46:811-8.
26. Lee CH, Chen HN, Tsao LY, Hsiao CC, Lee ML. Oral ibuprofen versus intravenous indomethacin for closure of patent ductus arteriosus in very low birth weight infants. Pediatr Neonatol 2012;53:346-53.
27. Yurttutan S, Oncel MY, Arayici S, Uras N, Altug N, Erdevi O, *et al.* A different first-choice drug in the medical management of patent ductus arteriosus: Oral paracetamol. J Matern Fetal Neonatal Med 2013;26:825-7.
28. Dang D, Wang D, Zhang C, Zhou W, Zhou Q, Wu H. Comparison of oral paracetamol versus ibuprofen in premature infants with patent ductus arteriosus: A randomized controlled trial. PLoS One 2013;8:e77888.