

---

## An interesting case of aorto-left ventricular tunnel

Sir,

Aorto-left ventricular tunnel is a congenital connection between ascending aorta and left ventricle. It is one of the rarest conditions with an estimated incidence of 0.001% of all cardiac malformations.<sup>[1]</sup> Clinical spectrum is varied; at one end of the spectrum, they can be asymptomatic, while at the other end, they can have congestive cardiac failure and aortic regurgitation.<sup>[1]</sup>

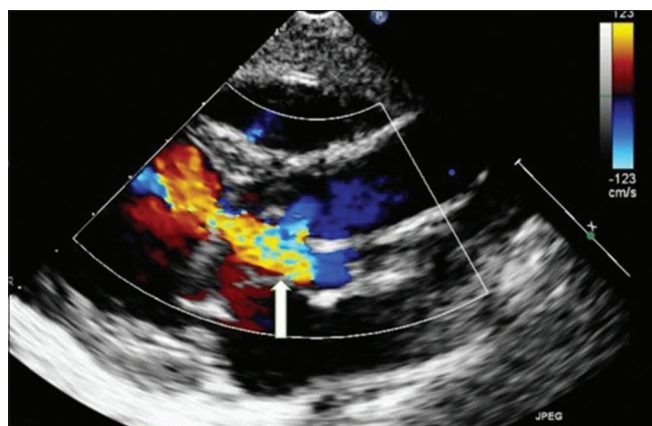
A 6-year-old female child was admitted to our hospital with complaints of fever, cough, and breathlessness on exertion, on and off for the past 1 year. General physical examination was unremarkable. On cardiovascular system examination, grade 3/6 systolic murmur was heard along the left sternal border. Electrocardiogram showed a heart rate of 95 beats/min, in sinus rhythm. Chest X-ray showed cardiothoracic ratio of 0.6. Transthoracic echocardiogram [Figure 1] showed aorto-left ventricular tunnel from left coronary-noncoronary commissure to the left ventricle at the base of noncoronary cusp. She was taken up for surgery. After establishing cardiopulmonary bypass with aorta and bicaval cannulation, aorta was cross-clamped. Aorta was transected and cold blood cardioplegia was given through the coronary ostia. Aortic end of the tunnel [Figure 2] was found as an opening extending behind the left coronary cusp-noncoronary cusp commissure into both sinuses. A silk thread [Figure 3] is passed from the opening in the noncoronary sinus, which came out through the opening in the left ventricle. Similarly, another silk thread is passed from the opening in the left coronary sinus, which also came out through the same opening in the left ventricle. On further examination, we found out that both the openings were found out to be single opening extending behind the commissure. The left ventricle end of the tunnel was

closed with 0.4-mm polytetrafluoroethylene (PTFE) patch using 6-0 polypropylene pledgeted interrupted sutures. Aortic end of the orifice was also closed with a small PTFE patch using 6-0 polypropylene pledgeted interrupted sutures. Aortic valve was inspected and commissure was resuspended on to the patch. The patient was weaned off from cardiopulmonary bypass gradually. Postoperative transesophageal echocardiogram revealed no communication between aorta and left ventricle. The patient is doing well without any symptoms at 1-year follow-up.

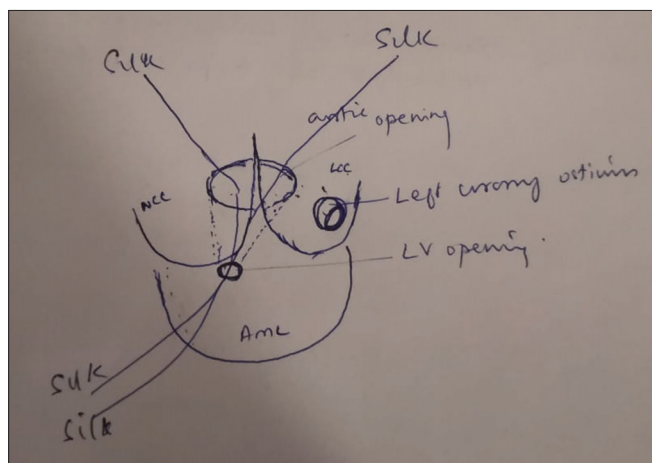
Hovaguimian *et al.*<sup>[2]</sup> defined four types of aorto-left ventricular tunnel. Most common site of origin of the aortic orifice of the tunnel is from the right coronary sinus, on the anterolateral side of the ascending aorta.<sup>[1]</sup> There are some rare instances of it originating from left coronary sinus.<sup>[3,4]</sup> In our patient, the aortic orifice of the tunnel originated from the left coronary-noncoronary commissure extending into both sinuses and the tunnel was posterolateral to the ascending aorta.

Clinical presentation depends upon the type of aorto-left ventricular tunnel with the development of congestive cardiac failure, common to all the types.<sup>[3,4]</sup>

Regardless of the presentation, even if the patient is asymptomatic, surgical treatment is advocated to prevent the development of complications such as aortic regurgitation and congestive cardiac failure. Best time for surgery is infancy because left ventricular function and size can become normal easily. Serino *et al.*<sup>[5]</sup> reported that closing the aortic defect by direct suture may result in progressive distortion of the cusps, which could result in regurgitation and the need for valve replacement. Hence, patch technique may be beneficial, which can act as a support to



**Figure 1:** Transthoracic echocardiogram in the parasternal long-axis view showing aorto-left ventricular tunnel from left coronary–noncoronary commissure to left ventricle at the base of noncoronary cusp



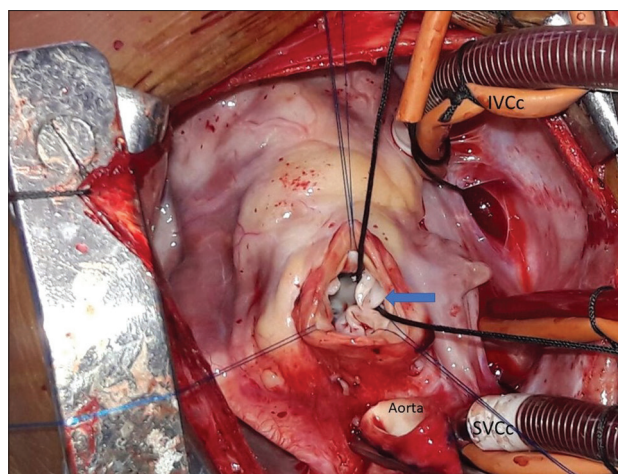
**Figure 3:** Line diagram showing silk passing through the aortic end of the tunnel, which was found as an opening extending behind the left coronary cusp–noncoronary cusp commissures into both sinuses

dilated aortic sinus. However, patch should be trimmed appropriately to avoid any distortion to aortic valve. Hence, we preferred to close both the sides of the tunnel using small 0.4 mm, appropriately trimmed PTFE patch.

To conclude, aorto-left ventricular tunnel is a rare extracardiac communication between aorta and left ventricle and if diagnosed should be operated immediately for the reasons stated above.<sup>[6]</sup>

#### Declaration of patient consent

The authors certify that they have obtained all appropriate patient consent forms. In the form the patient(s) has/have given his/her/their consent for his/her/their images and other clinical information to be reported in the journal. The patients understand



**Figure 2:** Intraoperative picture showing aortic end of the tunnel which was found as an opening extending behind the left coronary cusp–noncoronary cusp commissure into both sinuses

that their names and initials will not be published and due efforts will be made to conceal their identity, but anonymity cannot be guaranteed.

#### Financial support and sponsorship

Nil.

#### Conflicts of interest

There are no conflicts of interest.

**Musthafa Janeel, Swaminathan Vaidyanathan, Annie Arvind, Neville AG Solomon**

Department of Pediatric Cardiac Surgery, Apollo Children's Hospital, Chennai, Tamil Nadu, India.  
E-mail: [nevellesolomon@gmail.com](mailto:nevellesolomon@gmail.com)

Received: 28-02-2019 Revised: 31-03-2019

Accepted: 08-06-2019 Published: 26-07-2019

## REFERENCES

1. Yildirim A, Erek E, Uslu Z, Saygili A, Karaagac AT. Aorto-left ventricular tunnel originating from the left coronary sinus with aortic aneurysm in an 11-year-old boy. *Tex Heart Inst J* 2013;40:91-4.
2. Hovaguimian H, Cobanoglu A, Starr A. Aortico-left ventricular tunnel: A clinical review and new surgical classification. *Ann Thorac Surg* 1988;45:106-12.
3. Ono M, Goerler H, Boethig D, Breyman T. Surgical repair of aortico-left ventricular tunnel arising from the left aortic sinus. *Interact Cardiovasc Thorac Surg* 2008;7:510-1.
4. Nezafati MH, Maleki MH, Javan H, Zirak N. Repair of aorto-left ventricular tunnel arising from the left sinus of Valsalva. *J Card Surg* 2010;25:345-6.
5. Serino W, Andrade JL, Ross D, de Leval M, Somerville J. Aorto-left ventricular communication after closure. Late postoperative problems. *Br Heart J* 1983;49:501-6.

# Letters to Editor

6. Kathare P, Subramanyam RG, Dash TK, Muthuswamy KS, Raghu K, Koneti NR. Diagnosis and management of aorto-left ventricular tunnel. Ann Pediatr Cardiol 2015;8:103-7.

This is an open access journal, and articles are distributed under the terms of the Creative Commons Attribution-NonCommercial-ShareAlike 4.0 License, which allows others to remix, tweak, and build upon the work non-commercially, as long as appropriate credit is given and the new creations are licensed under the identical terms.

Access this article online	
Quick Response Code: 	Website: <a href="http://www.annalspc.com">www.annalspc.com</a>
	DOI: 10.4103/apc.APC_28_19

**How to cite this article:** Janeel M, Vaidyanathan S, Arvind A, Solomon NA. An interesting case of aorto-left ventricular tunnel. Ann Pediatr Card 2020;13:108-10.

© 2019 Annals of Pediatric Cardiology | Published by Wolters Kluwer - Medknow