

Criss-cross heart

Poster No.: C-1088
Congress: ECR 2015
Type: Educational Exhibit
Authors: N. Calvo Rado, M. Colom Seguí, M. Rodriguez Romero, E. R. Amador González, M. Pons Perelló, P. Roig Egea; Palma de Mallorca/ES
Keywords: Congenital, Imaging sequences, Education, MR, Paediatric, Cardiovascular system, Cardiac
DOI: 10.1594/ecr2015/C-1088

Any information contained in this pdf file is automatically generated from digital material submitted to EPOS by third parties in the form of scientific presentations. References to any names, marks, products, or services of third parties or hypertext links to third-party sites or information are provided solely as a convenience to you and do not in any way constitute or imply ECR's endorsement, sponsorship or recommendation of the third party, information, product or service. ECR is not responsible for the content of these pages and does not make any representations regarding the content or accuracy of material in this file.

As per copyright regulations, any unauthorised use of the material or parts thereof as well as commercial reproduction or multiple distribution by any traditional or electronically based reproduction/publication method is strictly prohibited.

You agree to defend, indemnify, and hold ECR harmless from and against any and all claims, damages, costs, and expenses, including attorneys' fees, arising from or related to your use of these pages.

Please note: Links to movies, ppt slideshows and any other multimedia files are not available in the pdf version of presentations.

www.myESR.org

Learning objectives

To describe an uncommon congenital heart disease and show its different forms of presentation.

To outline the different presentations to facilitate their study by MRI.

To describe the image interpretation of the main surgical techniques.

Background

Criss-cross heart is a rare and complex congenital cardiac malformation. The term criss-cross heart was first described by Anderson et al. in 1974. It occurs in 8 per 1,000,000 births, and is found in less than 0.1 % of congenital heart malformations. There are few cases described in the literature.

It is characterized by a ventricular rotation around its longitudinal axis conditioning intersecting ventricular inflow tracts. The atria are kept in their usual position ([Fig. 1](#) on page 5).

The etiology and the stage of embryologic development are not well known. There are some studies that suggest Cx43 gene mutation is the cause for criss-cross heart.

Criss-cross heart is frequently associated with other severe cardiac anomalies such as pulmonary stenosis, double-outlet right ventricle, ventricular septal defects and transposition of the great arteries. Other, less frequent defects, are subaortic stenosis, aortic arch obstruction and mitral stenosis.

The clinical picture depends on the different connections atrio-ventricular (AV) or ventriculo-arterial (VA) and the malformations. Due to these characteristics the clinical diagnosis is difficult. The initial study is usually made by echocardiography. MRI allows us to make an accurate diagnosis and observe the associated malformations.

Surgery is the treatment of choice because of the poor prognosis of the pathology. The initial treatment depends on the presence of pulmonary stenosis. In the cases of a severe stenosis the ductus arteriosus must remain open with prostaglandin to maintain a correct flow. When this fails, a systemic-pulmonary shunt is needed. The surgical correction is made a second time. The treatment of choice in criss-cross heart with double-outlet right ventricle or transposition of the great arteries consists in a biventricular repair. A patch in the septal defect and an atrial or arterial switch is necessary.

If corrective surgery cannot be performed (for example in cases of hypoplasia of the tricuspid valve ring and the right ventricle or the presence of straddling valves), a Glenn and Fontan technique is normally the treatment of choice.

The Glenn procedure is a temporary treatment performed in 3-8 month infants that consists in connecting the superior vena cava with the right pulmonary artery. Normally, the pulmonary trunk is closed. Nevertheless, in some cases, a supplementary blood

circulation from the pulmonary trunk (in this case there is not a complete closure of the pulmonary trunk) is necessary; or a systemic-pulmonary fistula.

The Fontan procedure is the definitive surgery. It is habitually performed on children of about 3 years old. It consists in inserting an extracardiac conduit between the inferior vena cava and the right pulmonary artery. Therefore all non-oxygenated blood from the systemic venous system passes directly to the pulmonary arterial circulation bypassing the heart.

Images for this section:

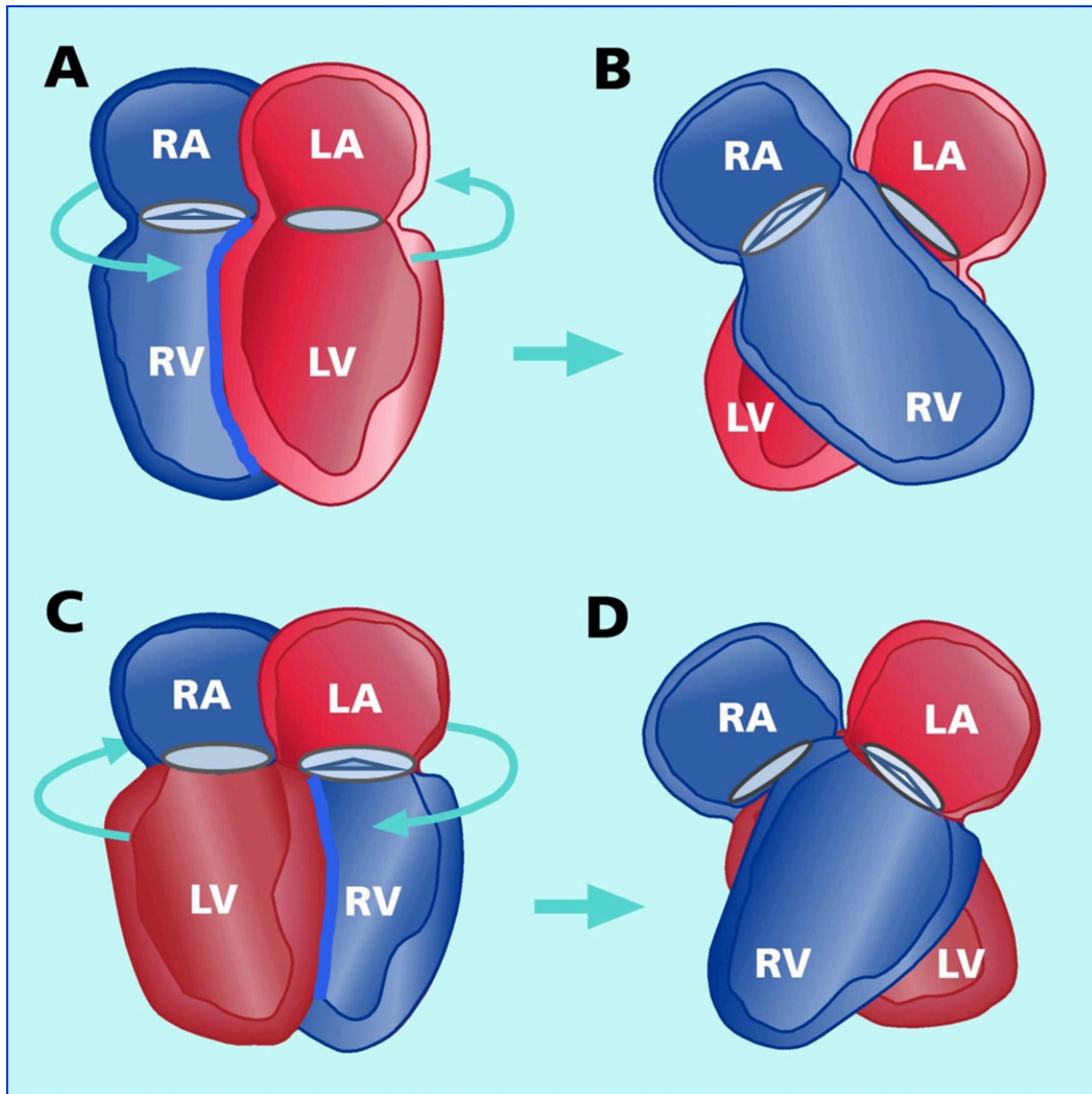


Fig. 1: A) Atrioventricular (AV) concordance. The meaning of ventricular rotation is counterclockwise. B) AV concordance with spacial relation discordant. Right atrium (RA) on the right connected with a right ventricle (RV) that is situated on the left and a left atrium (LA) on the left side connected with the left ventricle (LV) that it is on the right. C) AV discordance. The direction of ventricular rotation is clockwise. D) AV discordance with concordant spatial relation. RA on the right side is conected to a left LV and the LA on the left connected with a RV that it is located on the right.

© HU Son Espases - Palma de Mallorca/ES

Findings and procedure details

Ultrasound is a good imaging technique to make a diagnosis. Not displaying a four chamber views is typical of this entity. Some advantages of the MRI are that it displays the heart in all the spatial views required, and it also has a wider field of view. Moreover, it is possible to reconstruct the image in 3 dimensions.

MRI sequences in black blood, the cine (steady state free precession) sequences and the angiography study permit a comprehensive study of the disease, allowing us to recognize the different chambers of the heart based on their anatomy, and the relationship among them.

Due to the congenit heart disease complexity it is useful to analyze the heart in different parts (atria, ventricles and arteries) and the relationship between them.

There is some helpful information for the radiologist to clarify which chamber is each.

The right atrium has pectinate muscles in the wall and it regularly receives superior and inferior cava veins. The left atrium wall is smooth and receives blood from pulmonary veins. The right ventricle is characterized by trabeculae papillary muscles adherent to the interventricular septum. The left ventricle has thin trabeculae in the lateral and inferior walls. However it has no trabeculae in the septum and the anterior wall. The aortic root is usually located posterior and in the right side of the pulmonary artery.

The radiologist must identify the correct disposition of the chambers and vessels among the others. In a normal heart the AV connections are parallel and the VA connections are crossed. Criss-cross heart is characterized by a crossed AV connection. In this entity, a right atrium found on the right is communicated to a ventricle that is located on the left side and a left atrium found on the left is communicated to a ventricle that is located on the right side.

It is important to establish the kind of criss-cross heart: assessing AV concordance, AV spatial relationship and ventriculoarterial concordance. The type of surgical treatment depends on the kind of criss-cross heart. In addition, we have to look for associated malformations.

We present a criss-cross heart case to illustrate this condition. An 18-year-old man who was diagnosed with criss-cross heart with the following anomalies: interventricular septal defect, left aortic artery and severe pulmonary stenosis. The Glenn and Fontan procedures were performed. Due to Fontan conduit obstruction, a conduit replacement

was required. As a complication he had a right pulmonary artery stenosis. A stent was placed. A control MRI was performed.

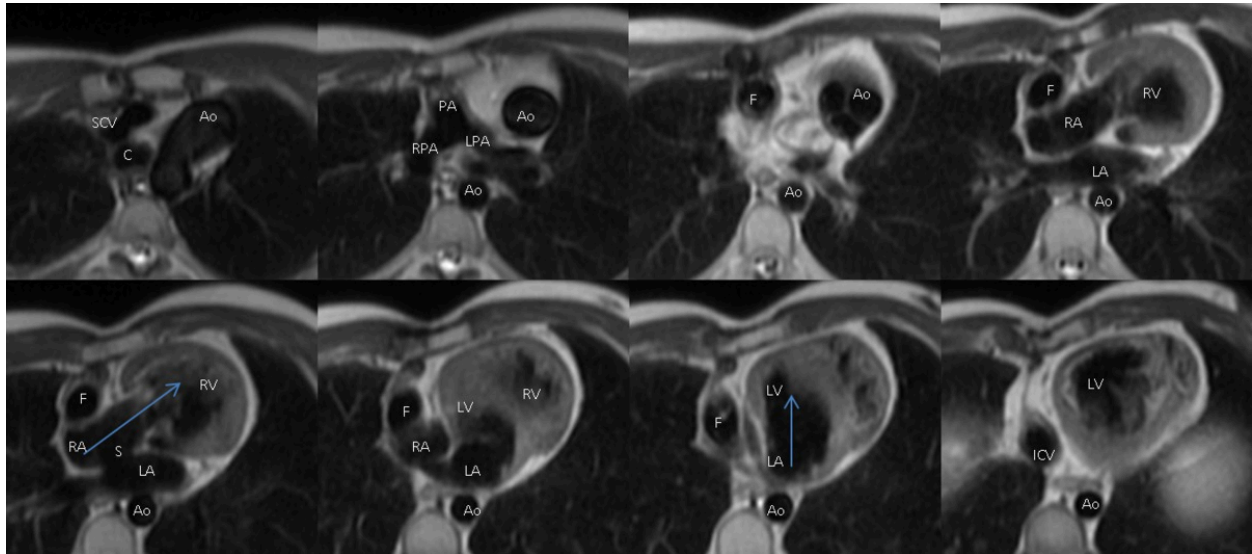


Fig. 2: Double inversion recovery T1 sequence. Transverse plane. The images show the intersecting ventricular inflow tracts (blue arrows). A right atrium found on the right is communicated to a ventricle that is located on the left side and in a upper position, and a left atrium found on the left is communicated to a ventricle that is located on the right side and lower position (AV concordance). Note: the aortic root is located on the left side. Interatrial septal resection can be observed. Ao: aorta, C: carina, F: Fontan, ICV: inferior cava vein, LA: left atrium, LPA: left pulmonary artery, LV: left ventricle, RA: right atrium, RPA: right pulmonary artery, RV: right ventricle, S: interatrial resected septum, SCV: superior cava vein.

References: HU Son Espases - Palma de Mallorca/ES

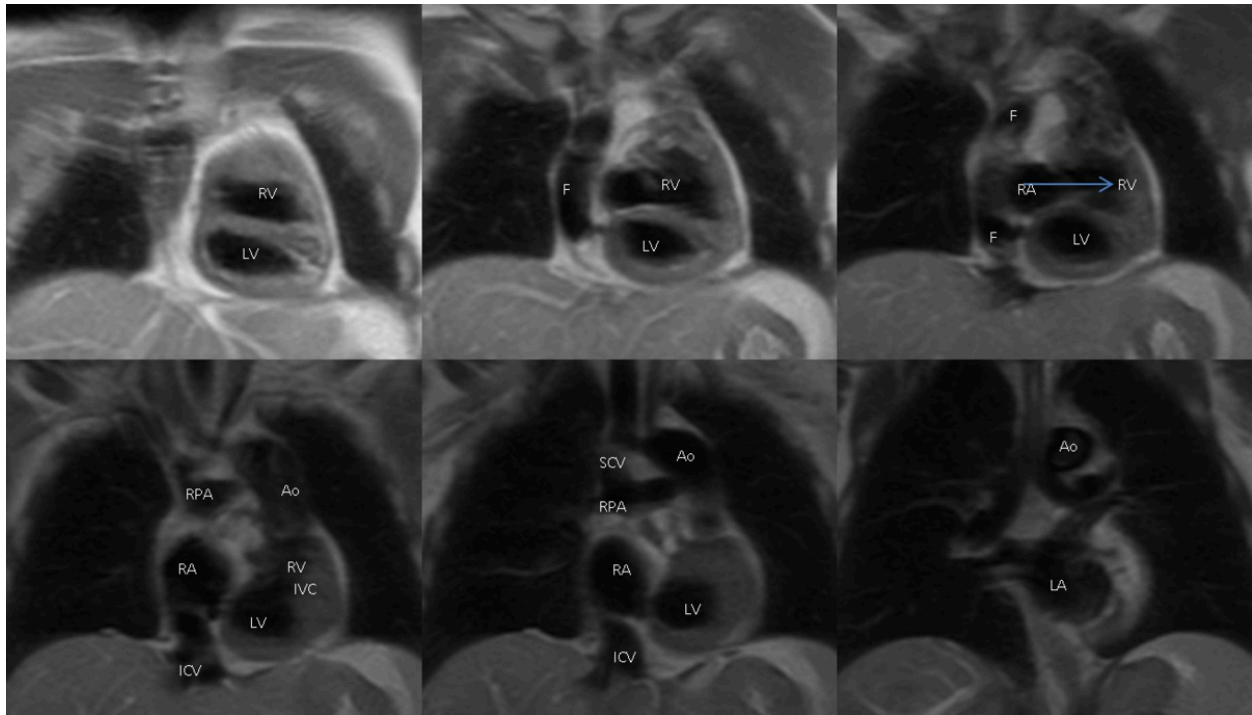


Fig. 3: Double inversion recovery T1 sequence. Coronal plane. The images show crossed AV connection. Fontan conduit can also be observed. Ao: aorta, F: Fontan, IVC: inferior cava vein, IVC: interventricular septal defect, LA: left atrium, LV: left ventricle, RA: right atrium, RPA: right pulmonary artery, RV: right ventricle, S: interatrial resected septum, SCV: superior cava vein.

References: HU Son Espases - Palma de Mallorca/ES

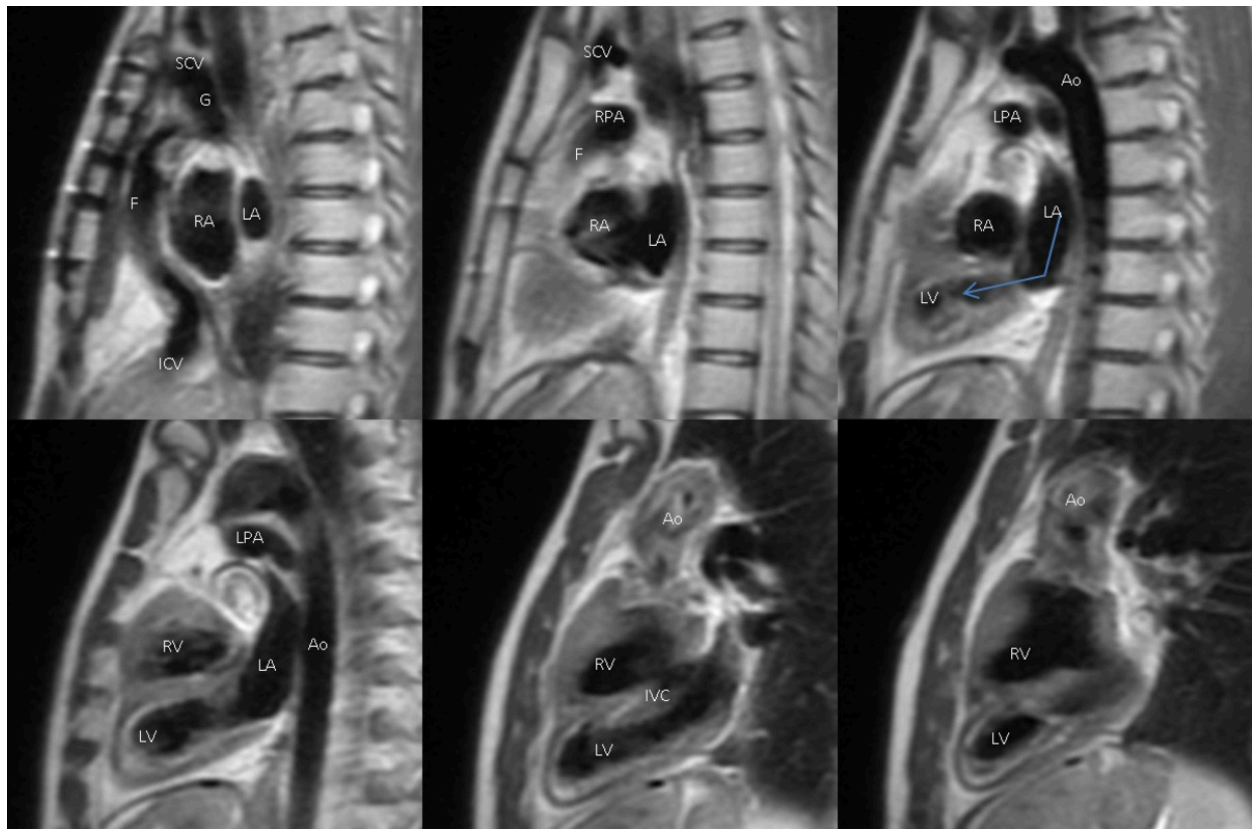


Fig. 4: Double inversion recovery T1 sequence. Sagittal plane. The images demonstrate intersecting ventricular inflow tracts. Interventricular septal defect can be well observed in this plane. Ao: aorta, F: Fontan, G: Glenn, IVC: inferior cava vein, IVC: interventricular septal defect, LA: left atrium, LPA: left pulmonary artery, LV: left ventricle, RA: right atrium, RPA: right pulmonary artery, RV: right ventricle, SCV: superior cava vein.

References: HU Son Espases - Palma de Mallorca/ES

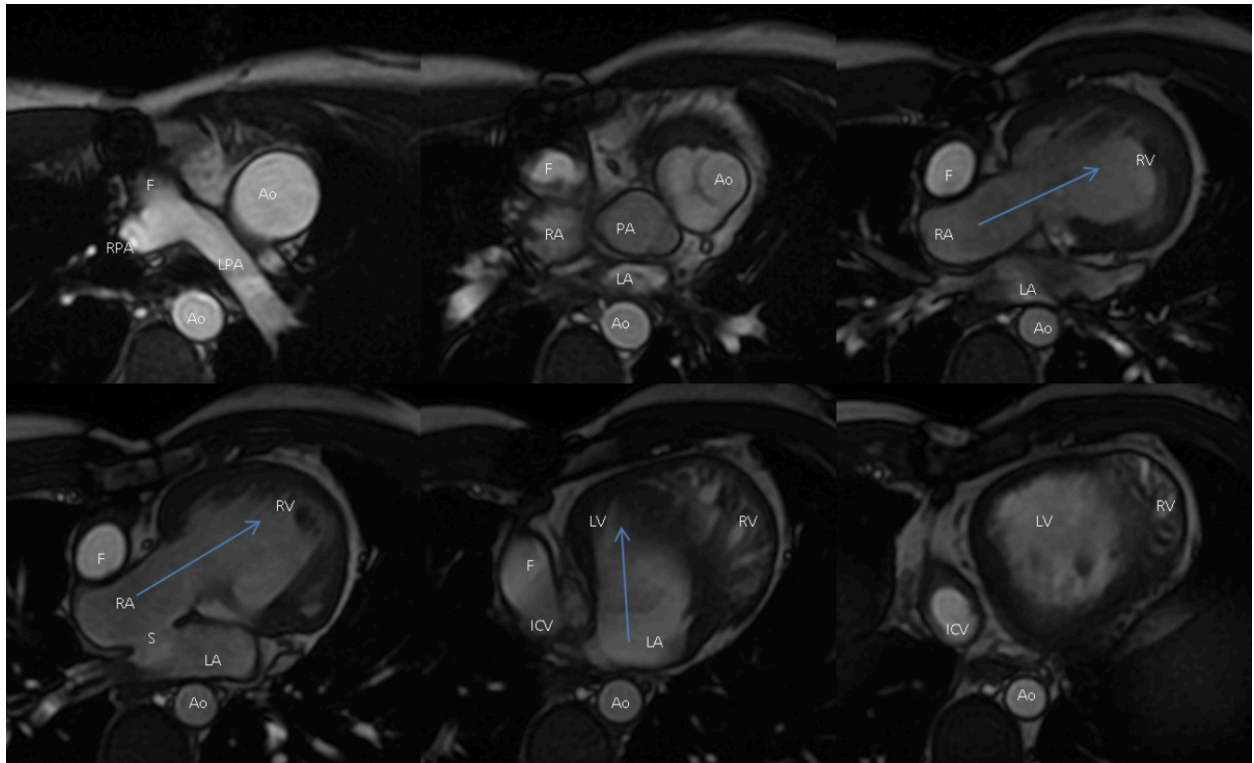


Fig. 5: Cine sequence. Transverse plane. The images show crossed AV connection (blue arrows). Right ventricle is communicated with the aorta that is located on the left side. The left ventricle is communicated with the pulmonary artery that is located on the right side (VA discordance). Ao: aorta, F: Fontan, ICV: inferior cava vein, LA: left atrium, LPA: left pulmonary artery, LV: left ventricle, PA: pulmonary artery, RA: right atrium, RPA: right pulmonary artery, RV: right ventricle, S: interatrial resected septum.

References: HU Son Espases - Palma de Mallorca/ES

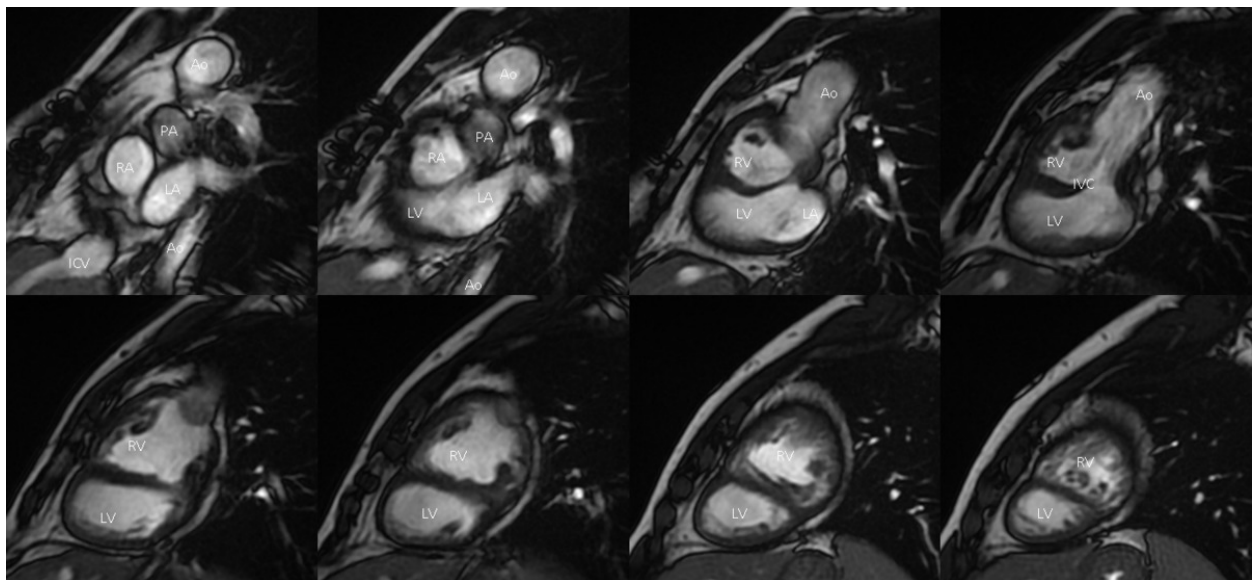


Fig. 6: Cine sequence. Short axis. The images demonstrate right ventricle communicating with the aorta. Ao: aorta, IVC: inferior cava vein, IVC: interventricular septal defect, LA: left atrium, LV: left ventricle, PA: pulmonary artery, RA: right atrium, RV: right ventricle.

References: HU Son Espases - Palma de Mallorca/ES

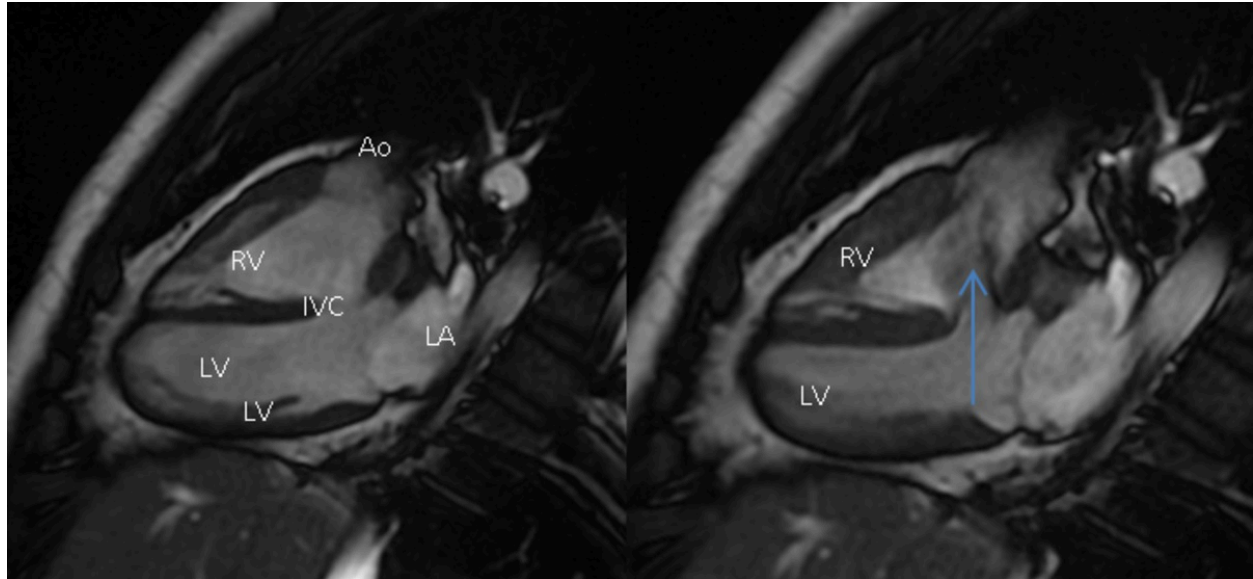


Fig. 7: Cine sequence. Long axis. The images show the interventricular septal defect. The flow through interventricular septal defect can also be observed (blue arrow). Ao: aorta, IVC: interventricular septal defect, LA: left atrium, LV: left ventricle, RV: right ventricle.

References: HU Son Espases - Palma de Mallorca/ES

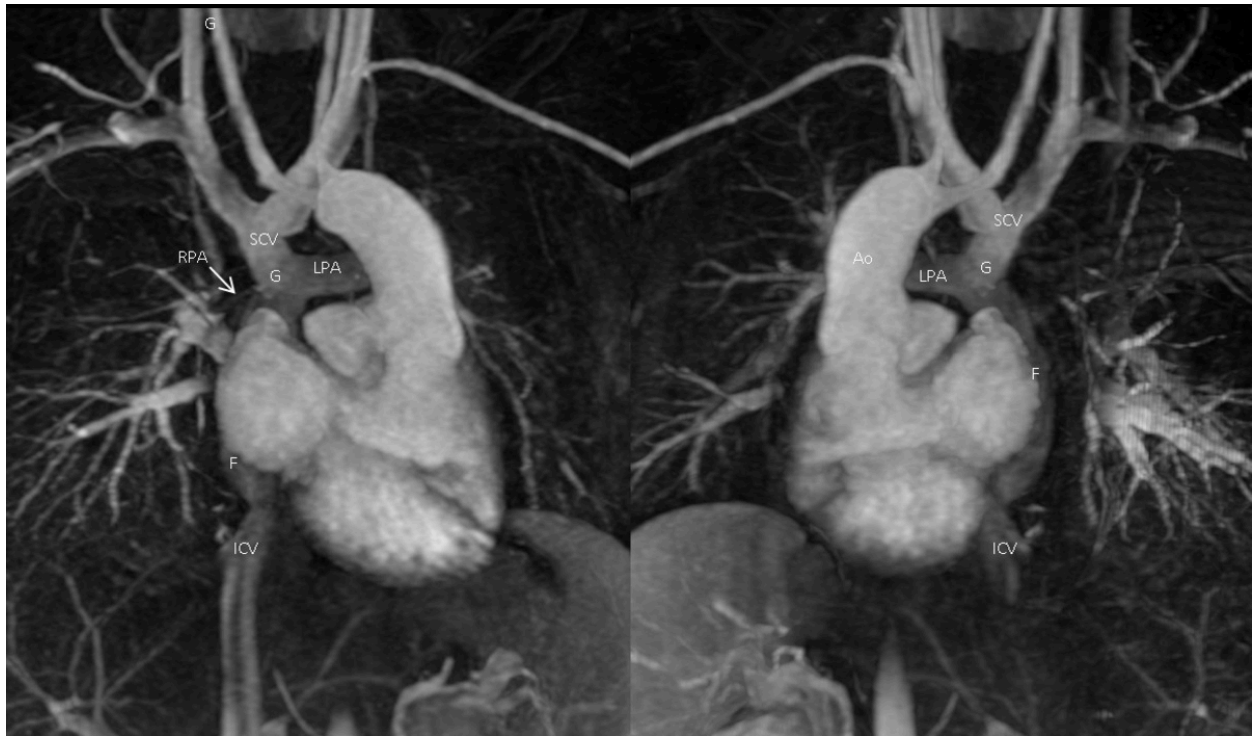


Fig. 8: Angiography sequence. 3 dimensions reconstruction. (anterior and posterior view) allows us to observe better the Glenn and Fontan procedures. Due to the stent on the right pulmonary artery (RPA) origin, RPA narrowing is overestimated. Ao: aorta, F: Fontan, G: Glenn, ICV: inferior cava vein, LPA: left pulmonary artery, RPA: right pulmonary artery, SCV: superior cava vein.

References: HU Son Espases - Palma de Mallorca/ES

Images for this section:

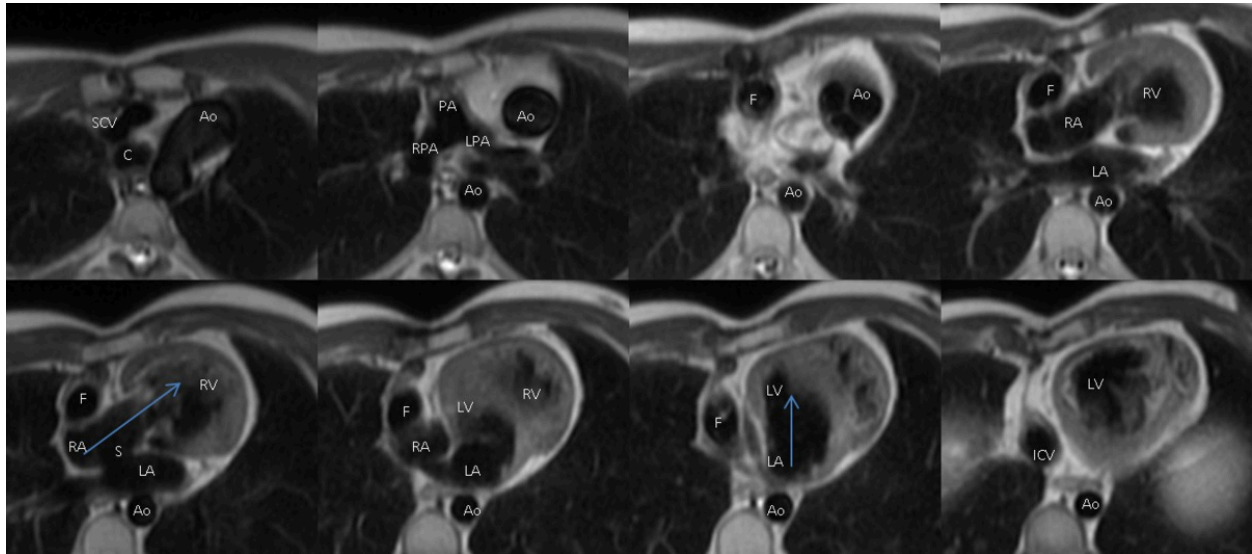


Fig. 2: Double inversion recovery T1 sequence. Transverse plane. The images show the intersecting ventricular inflow tracts (blue arrows). A right atrium found on the right is communicated to a ventricle that is located on the left side and in a upper position, and a left atrium found on the left is communicated to a ventricle that is located on the right side and lower position (AV concordance). Note: the aortic root is located on the left side. Interatrial septal resection can be observed. Ao: aorta, C: carina, F: Fontan, ICV: inferior cava vein, LA: left atrium, LPA: left pulmonary artery, LV: left ventricle, RA: right atrium, RPA: right pulmonary artery, RV: right ventricle, S: interatrial resected septum, SCV: superior cava vein.

© HU Son Espases - Palma de Mallorca/ES

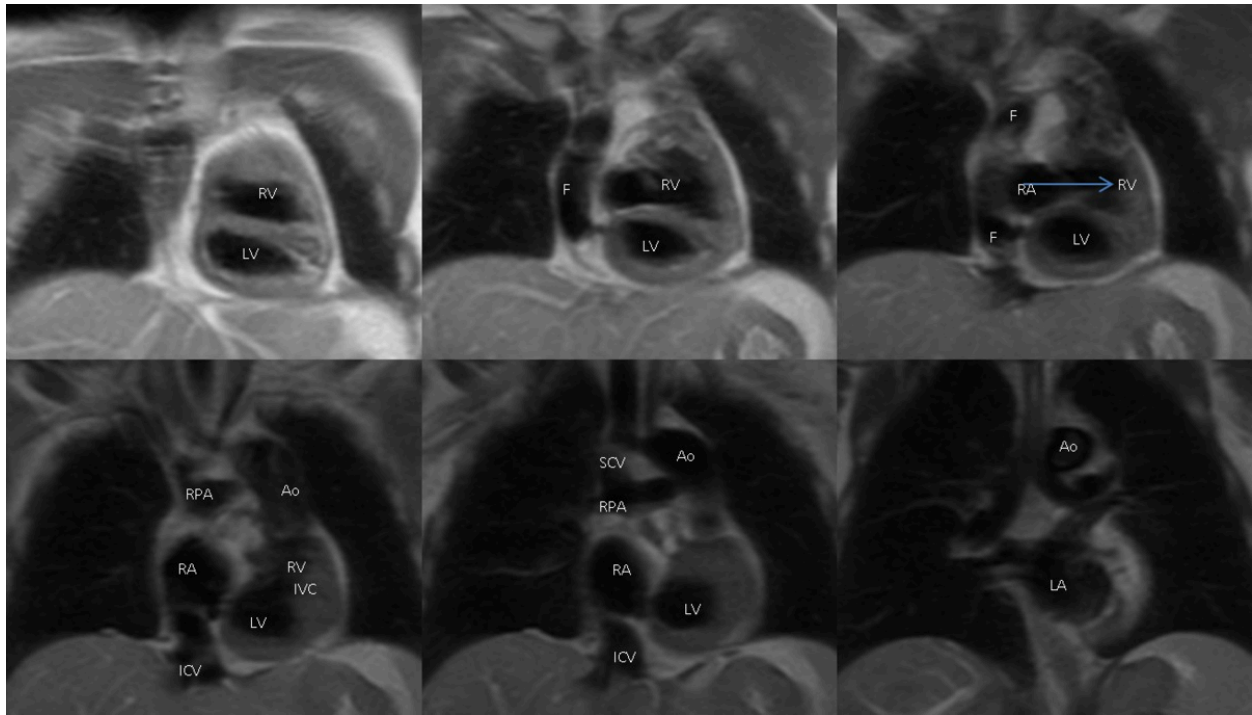


Fig. 3: Double inversion recovery T1 sequence. Coronal plane. The images show crossed AV connection. Fontan conduit can also be observed. Ao: aorta, F: Fontan, IVC: inferior cava vein, IVC: interventricular septal defect, LA: left atrium, LV: left ventricle, RA: right atrium, RPA: right pulmonary artery, RV: right ventricle, S: interatrial resected septum, SCV: superior cava vein.

© HU Son Espases - Palma de Mallorca/ES

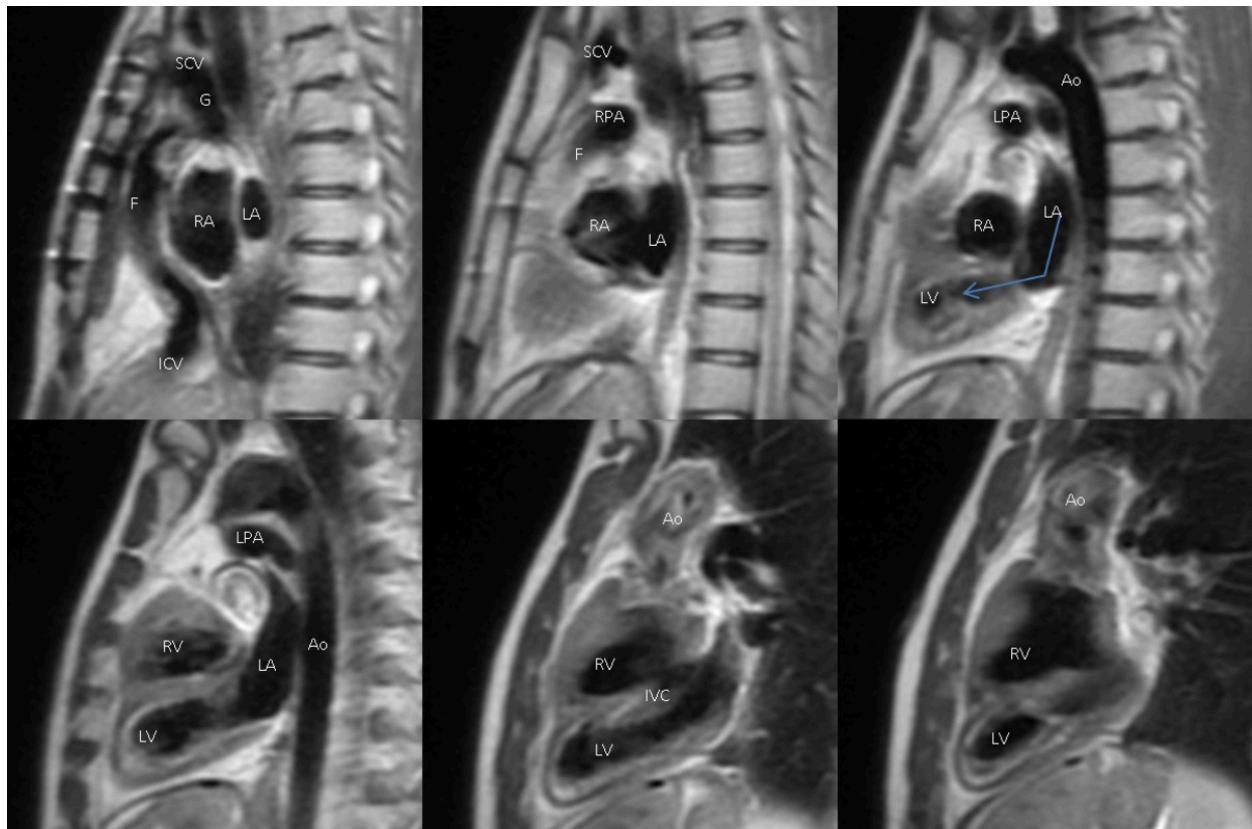


Fig. 4: Double inversion recovery T1 sequence. Sagittal plane. The images demonstrate intersecting ventricular inflow tracts. Interventricular septal defect can be well observed in this plane. Ao: aorta, F: Fontan, G: Glenn, IVC: inferior cava vein, IVC: interventricular septal defect, LA: left atrium, LPA: left pulmonary artery, LV: left ventricle, RA: right atrium, RPA: right pulmonary artery, RV: right ventricle, SCV: superior cava vein.

© HU Son Espases - Palma de Mallorca/ES

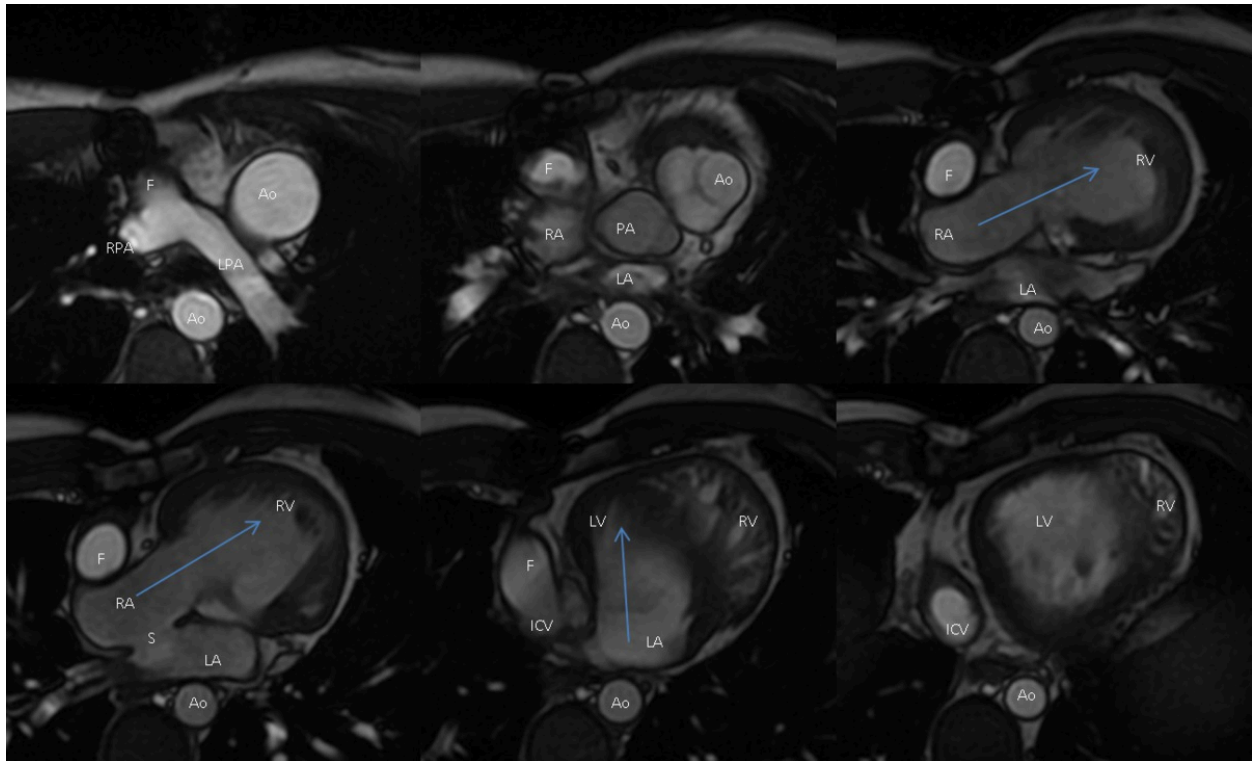


Fig. 5: Cine sequence. Transverse plane. The images show crossed AV connection (blue arrows). Right ventricle is communicated with the aorta that is located on the left side. The left ventricle is communicated with the pulmonary artery that is located on the right side (VA discordance). Ao: aorta, F: Fontan, ICV: inferior cava vein, LA: left atrium, LPA: left pulmonary artery, LV: left ventricle, PA: pulmonary artery, RA: right atrium, RPA: right pulmonary artery, RV: right ventricle, S: interatrial resected septum.

© HU Son Espases - Palma de Mallorca/ES

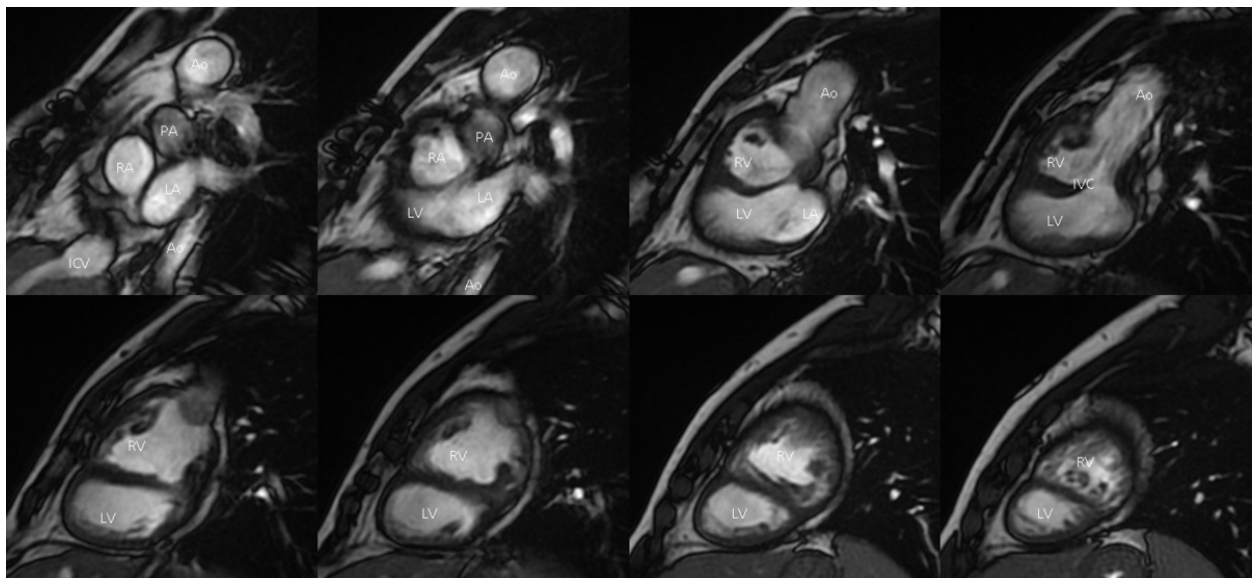


Fig. 6: Cine sequence. Short axis. The images demonstrate right ventricle communicating with the aorta. Ao: aorta, IVC: inferior cava vein, IVC: interventricular septal defect, LA: left atrium, LV: left ventricle, PA: pulmonary artery, RA: right atrium, RV: right ventricle.

© HU Son Espases - Palma de Mallorca/ES

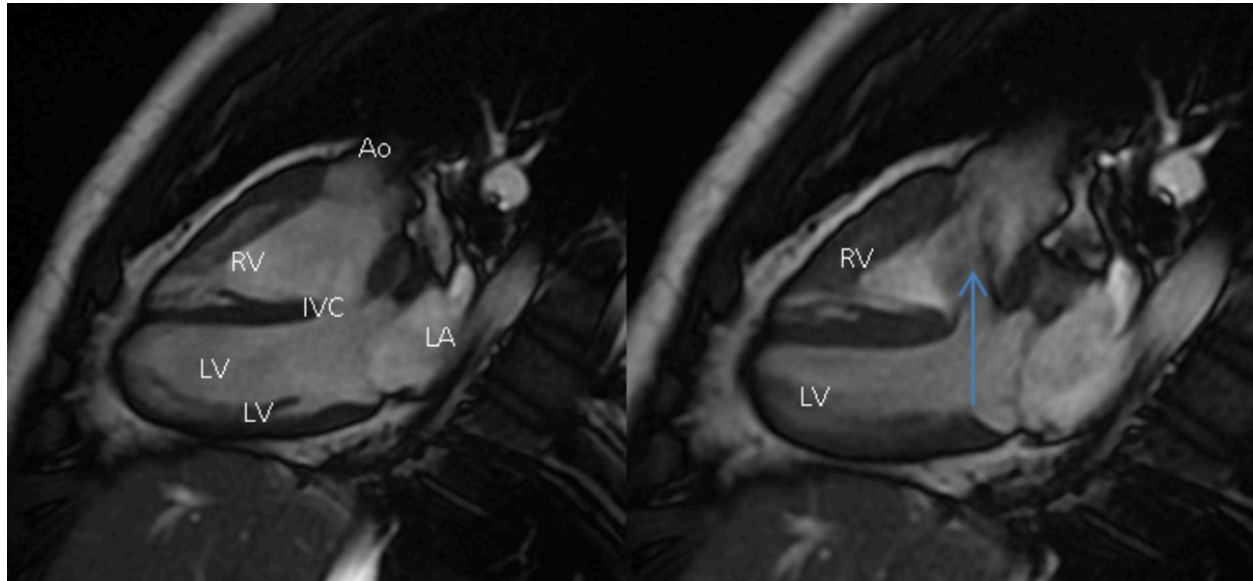


Fig. 7: Cine sequence. Long axis. The images show the interventricular septal defect. The flow through interventricular septal defect can also be observed (blue arrow). Ao: aorta, IVC: interventricular septal defect, LA: left atrium, LV: left ventricle, RV: right ventricle.

© HU Son Espases - Palma de Mallorca/ES

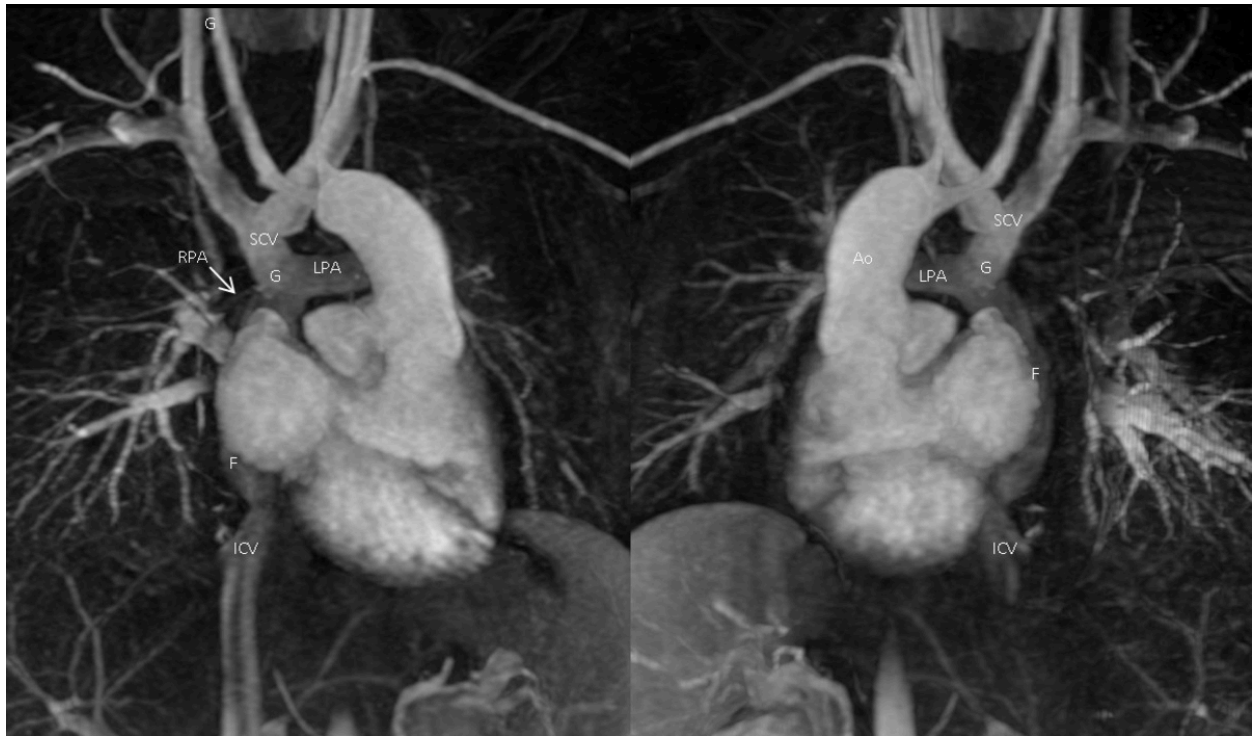


Fig. 8: Angiography sequence. 3 dimensions reconstruction. (anterior and posterior view) allows us to observe better the Glenn and Fontan procedures. Due to the stent on the right pulmonary artery (RPA) origin, RPA narrowing is overestimated. Ao: aorta, F: Fontan, G: Glenn, ICV: inferior cava vein, LPA: left pulmonary artery, RPA: right pulmonary artery, SCV: superior cava vein.

© HU Son Espases - Palma de Mallorca/ES

Conclusion

Criss-cross heart has a difficult diagnosis. MRI is the best image technique to evaluate this entity and all its complexity. MRI has a wide field of view and displays the heart in every spatial plane. It allows for a 3-dimensional image reconstruction.

A systematic analysis of cardiac anatomy using MRI facilitates the diagnosis of this condition.

It is very important to recognize all the associated malformations.

The knowledge of the principal surgeries allows us for a correct follow up of the patient.

References

Cantinotti M, Bell A, Hegde S, et al. A segmental approach to criss-cross heart by cardiac MRI. *Int J Cardiol* 118 (2007) e103-e105.

Yang YL, Wang XF, Cheng TO, et al. Echocardiographic characteristics of the criss-cross heart. *Int J Cardiol* 140 (2010) 133-137.

Oliveira IM, Aiello VD, Aguiar-Mindêllo MM, et al. Criss-cross heart: report of two cases, anatomic and surgical description and literature review. *Rev Bras Cir Cardiovasc* 2013;28(1):93-102.

Palmar AK, Guerra FE, Salas AM, et al. "Criss-cross con concordancia aurículo-ventricular y discordancia ventrículo-arterial" presentación clínica. *Avances Cardiol* 2011;31(3):254-259.

Messina-Cavellucci PMS, Suaide CE, Cortez-Ferreira LD, et al. Entrecruzamiento de las vías de entrada ventriculares (crisscross heart) y transposición anatómicamente corregida de las grandes arterias: relato de caso y revisión de literatura. *Rev bras ecocardiogr imagem cardiovasc.* 2012;25(4):292-297.